

DOI: 10.4274/jtad.galenos.2023.35220

J Turk Acad Dermatol 2023;17(4):106-108

## Lichenoid Drug Eruption Induced By COVID-19 mRNA Vaccine

© Tuğcan Yüksek<sup>1</sup>, © Selda Pelin Kartal<sup>1</sup>, © Evrim Önder<sup>2</sup>

<sup>1</sup>University of Health Sciences, Dışkapı Yıldırım Beyazıt Training and Research Hospital, Clinic of Dermatology, Ankara, Turkey

<sup>2</sup>University of Health Sciences, Dışkapı Yıldırım Beyazıt Training and Research Hospital, Clinic of Pathology, Ankara, Turkey

### ABSTRACT

**Keywords:** COVID-19, vaccine, mRNA, lichenoid reaction, drug eruption

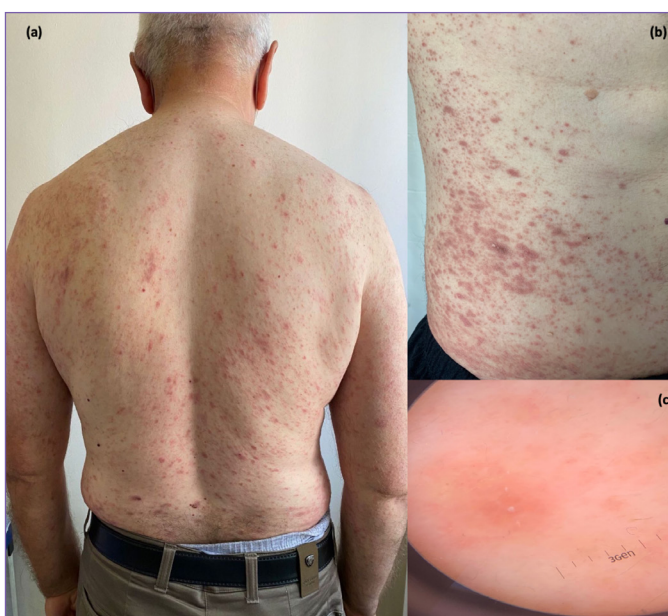#### Dear Editor,

As the worldwide vaccination campaign is going on rapidly against coronavirus disease-2019 (COVID-19) pandemic, the adverse cutaneous reactions are being studied extensively. While the most common cutaneous side effect is localized delayed injection-site reaction, there are different types of cutaneous reactions with different immunogenic mechanisms reported secondary to various COVID-19 vaccines [1]. Here in, we present a case of lichenoid drug eruption (LDE) in a male patient with no history of lichen planus (LP) occurred following administration of Pfizer-BioNTech (BNT162b2) mRNA COVID-19 vaccine.

A 57-year-old male patient with history of chronic hypertension treated with propranolol for 10 years, approached to our clinic with generalized itchy rash of 3-weeks duration. Detailed medical history revealed that he had the second dose of Pfizer-BionTech COVID-19 vaccine nine days prior to beginning of his complaints. The patient denied any additional medication use and a known history or any supporting symptom for COVID-19 preceding the skin eruption.

On physical examination, the patient was found to have multiple, slightly scaly, brownish-violaceous papules and plaques scattered mainly on the anterolateral sides of the trunk, back, flexural sides of both forearms and bilateral thighs (Figure 1A, B). There was no involvement of genital and oral mucosa or nails. Dermoscopic evaluation of the lesions revealed erythema, dotted vessels and

scales whereas Wickham's stria was not observed. (Figure 1C). The differential diagnoses included LDE, LP, pityriasis rosea and secondary syphilis. Routine laboratory tests revealed no pathologic



**Figure 1.** a) Symmetrical arrangement of violaceous papules and plaques on the back. b) Scaly, violaceous papules and plaques on the left flank. c) Dermoscopy: erythema, brownish pigmentation, dotted vessels, scales



**Address for Correspondence:** Tuğcan Yüksek, Asst., University of Health Sciences, Dışkapı Yıldırım Beyazıt Training and Research Hospital, Clinic of Dermatology, Ankara, Turkey

**Phone:** +90 312 596 12 18 **E-mail:** tugcanyukse6@gmail.com **ORCID ID:** orcid.org/0000-0003-2612-8080

**Received:** 27.04.2022 **Accepted:** 29.09.2023



Copyright© 2023 The Author. Published by Galenos Publishing House on behalf of the Society of Academy of Cosmetology and Dermatology. This is an open access article under the Creative Commons Attribution-NonCommercial-NoDerivatives 4.0 (CC BY-NC-ND) International License.

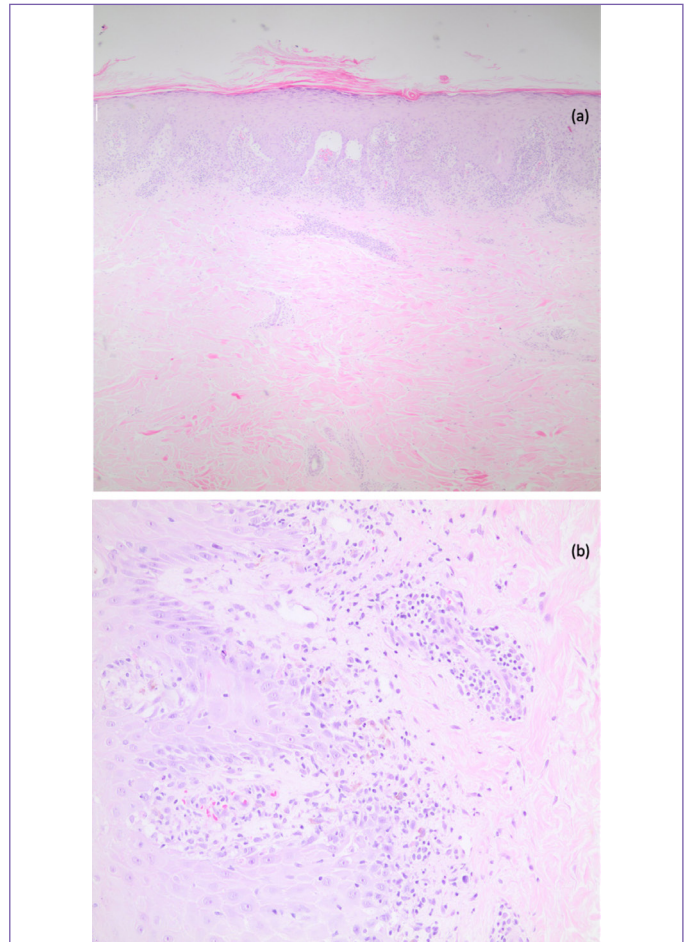
finding. Serology for Hepatitis B, C and human immunodeficiency virus, venereal disease research laboratory test and anti-nuclear antibody were normal. Severe acute respiratory syndrome-coronavirus-2 (SARS-CoV-2) polymerase chain reaction was tested negative.

Histopathological examination showed irregular acanthosis, dense lymphocytic infiltration at the dermoepidermal junction leading to separation of epidermis from the dermis, and few eosinophils (Figure 2A, B).

With clinicopathologic correlation, the patient was diagnosed as LDE triggered by COVID-19 vaccination. He was then administered 40 mg (0.5 mg/kg/daily) methylprednisolone combined with oral antihistamine and topical corticosteroids. Within a two-week period, as the patient’s symptoms subsided significantly, methylprednisolone was tapered over 3 weeks. The patient’s lesions were healed with post-inflammatory hyperpigmentation. During the 3-months of follow-up, the skin lesions did not recur. Written informed consent was obtained from the patient.

To date, as the mass vaccination against COVID-19 continues, various types of cutaneous reactions have been reported. Although delayed local injection site reactions are the most common type, urticaria, morbilliform rash, pernio/chilblains, pityriasis rosea-like reactions, dermal filler reactions, vasculitis, erythema-multiforme like rash are also well-recognized cutaneous reactions described following mRNA vaccines; Pfizer-BionTech or Moderna [2].

To our knowledge, lichenoid reactions secondary to COVID-19 vaccination is uncommon. Retrospective analysis of the case studies has shown that most of the reported cases were new-onset LP whereas LDE associated with COVID-19 vaccination is rarer (Table 1). In our case, the distribution and the morphology of the lesions,



**Figure 2.** a) Epidermal acanthosis, dense lymphocytic infiltration at the dermoepidermal junction (H&E x40). b) Eosinophils and melanophages accompanying lymphocytic infiltrate at the dermoepidermal junction (H&E x200)

**Table 1. Characteristics of lichenoid reactions reported after COVID-19 vaccines**

Patient	Age	Gender	Vaccine	Type of lichenoid reaction	Previous history	Time of onset after vaccination	Treatment given
1 <sup>1</sup>	56	Female	BNT162b2	LP	Present	2 days	Topical corticosteroids
2 <sup>2</sup>	56	Female	BNT162b2	LP	Absent	7 days	N/A
3 <sup>3</sup>	35	Female	N/A	Oral LP <sup>3</sup>	Absent	14 days	N/A
4 <sup>4</sup>	59	Female	BNT162b2	LP <sup>4</sup>	Present	14 days	Topical corticosteroids
5 <sup>5</sup>	53	Female	BNT162b2	LDE	Absent	12 days	Topical corticosteroids, oral antihistamines, oral prednisone
6 <sup>6</sup>	49	Male	Ad26.COVS.S	Oral LP	Absent	6 days	Topical corticosteroids
7 <sup>7</sup>	64	Female	BNT162b2	LP	Absent	5 days, recurrence 1 day after second dose	Topical and systemic corticosteroids
8 <sup>8</sup>	42	Female	BNT162b2	LS	Absent	3 days	Topical tacrolimus 0.1%
9 <sup>9</sup>	65	Female	N/A	Oral LP	Present	N/A	N/A
10 <sup>10</sup>	66	Male	AZD1222/ChAdOx1	LDE	Absent	5 days	Topical corticosteroids
11 <sup>11</sup>	52	Female	BBIBP-CorV	LP	Absent	10 days	Topical corticosteroids, oral antihistamines

LP: Lichen planus, LDE: Lichenoid drug eruption, LS: Lichen striatus, N/A: Not applicable, COVID-19: Coronavirus disease-2019

absence of mucosal involvement and Wickham's stria and the presence of eosinophils in histopathological specimen led to the diagnosis of BNT162b2-induced LDE rather than LP [3].

LDE has been linked with a diverse group of medications. However, LDE triggered by vaccination is rather rare in literature. There are few cases described after Hepatitis B, influenza, Hepatitis A and human papillomavirus vaccinations [4,5].

Although, the exact mechanism is yet to be clarified, it has been suggested that the BNT162b2 vaccine prompts an upregulation of Th1 response, which increases the levels of proapoptotic Th1 cytokines; interleukin-2, interferon gamma, and tumor necrosis factor alpha that causes a lichenoid inflammation by inducing apoptosis of keratinocytes in the basal layer of the dermis [6].

It can also be postulated that spike protein, which is the target antigen of the SARS-CoV-2 mRNA vaccines have common epitopes with the basal keratinocytes that may cause an immune reaction by activating CD8+ auto-cytotoxic T lymphocytes. Also, it should be noted that, although it is more commonly associated with mRNA vaccines, there are cases of lichenoid reactions described with other types of vaccines including inactivated and vector-based vaccines as well (Table 1). In addition, in literature there are some cases of oral LP following COVID-19 infection. Therefore, it can be suggested that the direct immunogenicity of the viral component of the vaccines rather than a specific ingredient is more likely to be the triggering factor for the post-vaccine lichenoid reactions as there are cases reported with various types of vaccines with different adjuvants.

In conclusion, LDE can be seen as a rare cutaneous adverse reaction of the BNT163b2 mRNA COVID-19 vaccine. However, there are cases of lichenoid reactions associated with vector-based or inactive vaccines as well. Although the exact pathogenesis has not been clearly explained, it is likely that the viral component of the COVID-19 vaccines is the main triggering factor leading to a cell-mediated immune response by T lymphocytes. As the pandemic continues with emerging variants of SARS-CoV-2, sustaining the worldwide vaccination process is still crucial despite the potential side effects. Therefore, dermatologists should be eligible to diagnose and if required, treat the cutaneous adverse reactions related with COVID-19 vaccines. Also, it should be noted that it

is important for dermatologists to examine vaccination history besides medication history in patients presented with clinical features of LDE.

### Ethics

**Informed Consent:** Written informed consent was obtained from the patient.

**Peer-review:** Externally peer-reviewed.

### Authorship Contributions

Surgical and Medical Practices: T.Y., S.P.K., Concept: T.Y., S.P.K., Design: T.Y., S.P.K., Data Collection or Processing: T.Y., E.Ö., Analysis or Interpretation: T.Y., S.P.K., E.Ö., Literature Search: T.Y., S.P.K., Writing: T.Y., S.P.K.

**Conflict of Interest:** No conflict of interest was declared by the authors.

**Financial Disclosure:** The authors declared that this study received no financial support.

### References

1. Niebel D, Novak N, Wilhelmi J, Ziob J, Wilsmann-Theis D, Bieber T, Wenzel J, Braegelmann C. Cutaneous Adverse Reactions to COVID-19 Vaccines: Insights from an Immuno-Dermatological Perspective. *Vaccines (Basel)* 2021;9:944.
2. McMahon DE, Amerson E, Rosenbach M, Lipoff JB, Moustafa D, Tyagi A, Desai SR, French LE, Lim HW, Thiers BH, Hruza GJ, Blumenthal KG, Fox LP, Freeman EE. Cutaneous reactions reported after Moderna and Pfizer COVID-19 vaccination: A registry-based study of 414 cases. *J Am Acad Dermatol* 2021;85:46-55.
3. Halevy S, Shai A. Lichenoid drug eruptions. *J Am Acad Dermatol* 1993;29:249-255.
4. Lai YC, Yew YW. Lichen planus and lichenoid drug eruption after vaccination. *Cutis* 2017;100:E6-E20.
5. Laschinger ME, Schleichert RA, Green B. Lichenoid drug eruption after human papillomavirus vaccination. *Pediatr Dermatol* 2015;32:e48-e49.
6. Sahin U, Muik A, Derhovanesian E, Vogler I, Kranz LM, Vormehr M, Baum A, Pascal K, Quandt J, Maurus D, Brachtendorf S, Lörks V, Sikorski J, Hilker R, Becker D, Eller AK, Grütznert J, Boesler C, Rosenbaum C, Kühnle MC, Luxemburger U, Kemmer-Brück A, Langer D, Bexon M, Bolte S, Karikó K, Palanche T, Fischer B, Schultz A, Shi PY, Fontes-Garfias C, Perez JL, Swanson KA, Loschko J, Scully IL, Cutler M, Kalina W, Kyratsous CA, Cooper D, Dormitzer PR, Jansen KU, Türeci Ö. COVID-19 vaccine BNT162b1 elicits human antibody and TH1 T cell responses. *Nature* 2020;586:594-599.