

DOI: 10.4274/jtad.galenos.2021.76376

J Turk Acad Dermatol 2022;16(2):50-52

# Secukinumab-induced Behçet's Disease in a Patient with Ankylosing Spondylitis Successfully Treated with Certolizumab: A Case Report

© Yusuf Karabulut

Doruk Private Hospital, Clinic of Internal Medicine, Division of Rheumatology, Bursa, Turkey

## ABSTRACT

Interleukin (IL)-17A is pro-inflammatory cytokine and plays a vital role in the pathogenesis of a range of immune-mediated diseases, including psoriasis, psoriatic arthritis, and ankylosing spondylitis (AS). Moreover, IL-17A plays protective roles in immune defense against certain pathogens at epithelial and mucosal barriers. Blocking IL-17A may be efficient to treat those immune-mediated diseases, but on the other hand it may trigger other immune related diseases such as Behçet's disease (BD) or Crohn's disease (CD). IL-17A blockers are newly introduced alternative treatment for AS patients but careful clinical assessment of comorbidities and patient history are required before making therapeutic choice. This case presentation reports a secukinumab induced BD in patient diagnosed with AS successfully treated with certolizumab pegol. IL-17A blockage is important in the treatment of AS. However, patients having comorbid disorders including BD, CD or other inflammatory bowel diseases must be treated with anti-TNFs rather than IL-17A blocker treatment.

**Keywords:** Ankylosing spondylitis, Behçet's disease, Interleukin (IL)-17A, Certolizumab, Case report

## Introduction

Interleukin (IL)-17A is pro-inflammatory cytokine [1] and plays a vital role in the pathogenesis of a range of immune-mediated diseases, including psoriasis (PsO), psoriatic arthritis (PsA), and ankylosing spondylitis (AS) [2]. PsO, PsA, and AS having considerable overlapping genetic features in pathogenesis [2]. Due to common etiologic heritage, treatment related adverse events and complications may occur in the same manner.

IL-17's pro-inflammatory and damaging effects have also been linked to pathogenic processes of other autoimmune diseases like rheumatoid arthritis (RA), Crohn's disease (CD) and Behçet's disease (BD) [3]. Blocking IL-17 was regarded as an alternative pathway and secukinumab was first in class molecule. As an IL-17A blocker, safety

and efficacy of secukinumab are clinically tested in PsO, PsA, AS, RA, CD and BD [3].

Pivotal studies revealed clinical success in AS, PsO and PsA and as a fully human monoclonal antibody, secukinumab received Food and Drug Administration approval for moderate-to-severe plaque PsO, PsA, and AS [3].

However, clinical studies in RA, CD and BD were not successful, secukinumab failed to demonstrate clinical improvement in these disorders. Besides there are recent case reports demonstrating potential triggering role of secukinumab in PsO, CD and BD [4,5,6]. Existing data prove benefit of targeting IL-17 therapeutically, however clinicians should consider paradoxical reactions and risks related with secukinumab. This case study reports a secukinumab induced BD patient successfully treated with certolizumab pegol (CZP).



**Address for Correspondence:** Yusuf Karabulut, MD, Doruk Private Hospital, Clinic of Internal Medicine, Division of Rheumatology, Bursa, Turkey

**Phone:** +90 532 221 14 92 **E-mail:** yusufkarabulut.dr@gmail.com **ORCID ID:** orcid.org/0000-0003-2690-6196

**Received:** 01.05.2021 **Accepted:** 10.05.2021

©Copyright 2022 by the Society of Academy of Cosmetology and Dermatology / Journal of the Turkish Academy of Dermatology published by Galenos Publishing House.

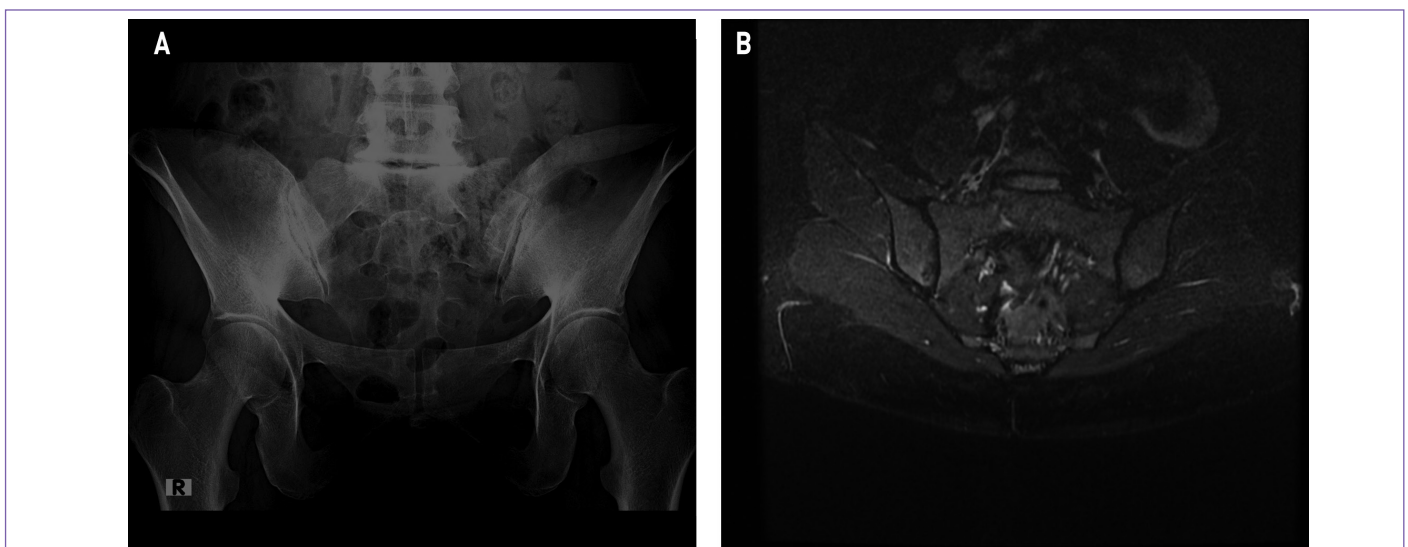
## Case Report

A thirty-four-year-old female was admitted to rheumatology outpatient service with gradually increasing pain in April 2019. Her widespread complaints of low back pain, morning stiffness (more than 1 hour), hip pain, night pain, and sleeping disorder were present with 12 months history. During her painful periods she took non-steroidal anti-inflammatory drugs (NSAID). Chosen medication had limited effect on pain, her morning stiffness and sleeping problems progressively worsened. On admission, her physical examination revealed increased sensitivity at both Achilles tendon. She had also limited spinal mobility and cervical rotation. Considering the patient history, ten years ago she was referred to dermatology clinic due to erythema nodosum and genital ulcers. In her comprehensive assessment she had accompanying oral ulcers and was diagnosed with BD. Her pathergy test and human leukocyte antigen (HLA) B51 test results were positive. After diagnosis, she took steroid and colchicum dispert for five years. Once her complaints disappeared then all medication terminated because of remission. During this remission period there were no relapses or attacks related with BD. Radiographic and serologic evaluation were also consistent with preliminary physical examination findings (Figure 1A, B). Her HLA-B27 was positive and C-reactive protein levels were elevated. Her magnetic resonance imaging findings showed inflammatory lesions and regarded as grade II sacroiliitis. However, her x-ray findings were clear and there were no radiologic changes. First day Bath Ankylosing Spondylitis Disease Activity index score was 6.8 and patient diagnosed as AS and BD in remission medication regimen planned.

## Treatment

On the second day of diagnosis, following a detailed evaluation with division of infectious diseases and radiology, biologic treatment was planned. From patient history we knew she took NSAID during painful periods and it was not efficient to heal pain or lower disease activity. Because of high titers of acute phase reactants, absence of any biologic treatment and HLA-B27 positivity, IL-17 blocker secukinumab (Verxant/Cosentyx) treatment planned. In May 2019, secukinumab treatment initiated. The recommended dose is 150 mg by subcutaneous injection with initial dosing at weeks 0, 1, 2, 3 and 4, followed by monthly maintenance dosing. At the fifth initial dose, there were observable improvement in her complaints of inflammatory back pain and enthesitis in Ascilles tendon. Following fifth dose, patient applied to clinic with mono-arthritis and oral ulcers. Due to BD reactivation, colchicum dispert and prednisone added to treatment. Three days later, she was re-admitted to clinic with widespread erythema nodosum in lower extremity. Following BD reactivation, prednisolone dose increased to 0.5 mg/kg/day and secukinumab treatment terminated.

Because of gradually progressing back pain, mono arthritis and difficulties in mobility, patient was prescribed CZP along with prednisone. At the second week of CZP treatment, we have added indomethacin 75 mg/day and pantoprazole 40mg/day. Following the first cure of anti-TNF treatment, all clinical findings related with AS and BD showed significant improvement. Our patient is under follow-up without low diseases activity under CZP maintenance treatment, prednisone 2.5 mg/day and colchicum dispert.



**Figure 1.** X-ray (a) and MRI (b) findings of patient. Radiographic findings were consistent with ASAS diagnosis criteria. Bilateral Grade II sacroiliitis seen in MRI (b)

MRI: Magnetic resonance imaging, ASAS: Assessment of Spondyloarthritis International Society

## Discussion

IL-17A is pro-inflammatory cytokine [1] and plays a vital role in the pathogenesis of a range of immune-mediated diseases. Moreover, IL-17A play protective roles in immune defense against certain pathogens at epithelial and mucosal barriers. It has also been reported that IL-17A-producing cells are detected upon infection with intracellular bacteria such as *Mycobacterium tuberculosis*, *Listeria monocytogenes* and *Salmonella typhimurium* [1]. Recent case reports demonstrating potential triggering role of secukinumab in PsO, CD and BD [4-6] are linked to IL-17A's protective roles in bacteria.

Secukinumab as an IL-17A blocker, clinically tested both in BD and CD. The multicenter Phase II trial on secukinumab in 59 patients with moderate-to-severe CD was prematurely terminated. Secukinumab did not help in improving conditions of patients with CD; moreover, worsening of the disease was reported as reflected in the high rate of serious adverse events as well as fungal infections [3].

Accordingly, elevated levels of IL-17A have been also found in the peripheral blood of patients with Behçet uveitis and as such it has been considered important in disease mechanisms [4]. With this hypothesis, a 24-week, randomized, double-blinded, placebo-controlled phase III trial was conducted in 118 Behçet's patients with posterior and pan-uveitis to assess the efficacy of secukinumab versus placebo adjunctive to standard-of-care immunosuppressive therapy [3]. This study also failed to demonstrate clinical improvement. Secukinumab showed a similar rate of recurrent ocular exacerbations with placebo during 24 weeks of treatment [3]. Further investigational studies with larger groups with secukinumab were halted.

This article is one of the first case presentations reporting potential role of Secukinumab in BD. IL-17A blockage is important in the treatment of AS. However, patients having comorbid disorders including BD, CD or other inflammatory bowel diseases must be treated with anti-TNFs rather than IL-17A blocker treatment. Since we have alternatives in the treatment of AS, such cases must be disregarded for IL-17A therapy.

## Ethics

**Informed Consent:** Written consent obtained from patient for the case presentation.

**Peer-review:** Externally peer-reviewed.

**Financial Disclosure:** The author declared that this study received no financial support.

## References

1. Jin W, Dong C. IL-17 cytokines in immunity and inflammation. *Emerg Microbes Infect* 2013;2:e60.
2. Deodhar A, Mease PJ, McInnes IB, Baraliakos X, Reich K, Blauvelt A, Leonardi C, Porter B, Das Gupta A, Widmer A, Pricop L, Fox T. Long-term safety of secukinumab in patients with moderate-to-severe plaque psoriasis, psoriatic arthritis, and ankylosing spondylitis: integrated pooled clinical trial and post-marketing surveillance data. *Arthritis Res Ther* 2019;21:111.
3. Koenders MI, van den Berg WB. Secukinumab for rheumatology: development and its potential place in therapy. *Drug Des Devel Ther* 2016;10:2069-2080.
4. Dincses E, Yurttas B, Esatoglu SN, Melikoglu M, Hamuryudan V, Seyahi E. Secukinumab induced Behçet's syndrome: a report of two cases. *Oxf Med Case Reports* 2019;5:omz041.
5. Dogra S, Bishnoi A, Narang T, Handa S. Secukinumab-induced paradoxical pustular psoriasis. *Clin Exp Dermatol* 2019;44:72-73.
6. Shiga H, Fukuda S, Iijima K. Interleukin-17A Inhibitor-induced Crohn's Disease/Behçet's Disease-like Lesions. *Inflamm Bowel Dis* 2017;23:E38-39.