

DOI: 10.4274/jtad.galenos.2021.68077

J Turk Acad Dermatol 2021;15(2):49-52

Rituximab and IVIG for the Treatment of Bullous Pemphigoid: Critical Analysis of the Current Literature

© Melis Gönülal, © Didem Didar Balci

University of Health Sciences Turkey, Izmir Tepecik Training and Research Hospital, Clinic of Dermatology, Izmir, Turkey

ABSTRACT

Bullous pemphigoid (BP) is the most common subepidermal autoimmune blistering disease. We want to present a case with resistant BP accompanied by telling both clinical features and treatments. A 67 year-old female with diabetes mellitus (DM) applied to dermatology outpatient clinic because of pruritus. Our patient didn't receive complete clinical response with the treatments of methylprednisolone aceponate lotion, bilastine tablet, omalizumab, oral steroid, azathioprine and tetracycline. In addition, she became insulin dependent DM because of oral steroid and azathioprine raised the levels of her liver enzymes. We had to stop these treatments. Now our patient is in remission with the treatments of rituximab and intravenous immunoglobulin (IVIG). We used rituximab and IVIG which are combined last step treatment regimens for our case and achieved to treat her. We think that our case report will contribute to literature because such difficult, rare cases may appear to clinicians at any time and our case may be a guide for clinicians.

Keywords: Bullous pemphigoid, Rituximab, Intravenous immunoglobulin

Introduction

Bullous pemphigoid (BP) is the most common subepidermal autoimmune blistering disease. Clinically, it is characterized by tense blisters with widespread erythema. Histology reveals subepidermal bullae with eosinophil infiltration and linear deposition of immunoglobulin (Ig) G and/or C3 along the basement membrane zone. Dementia, Parkinson's disease, psychiatric disorders, and blood disorders may associate with BP. Clinicians diagnose BP with clinical features, histology of lesions taken by skin biopsies, direct immunofluorescence and serum indirect immunofluorescence, (enzyme-linked immunosorbent assay) [1]. The non-collagenous 16A (NC16A) domain of BP180 and C-terminal domain of BP230 are the major epitopes of BP [2]. IgG against the NC16A domain of BP180 can be found in >90% of BP patients and autoantibodies against BP230 can be found in only 60% of BP patients [3]. Most of patients

respond to first step treatments but rarely patients unresponsive to treatments can exist. We want to present a case with resistant BP accompanied by telling both clinical features and treatments. We have received the informed consent form from the patient.

Case Report

A 67 year-old female with diabetes mellitus (DM) applied to dermatology outpatient clinic of Izmir Tepecik Training and Research Hospital because of pruritus that had been going on for two months. The patient said that sometimes urticaria like papules occurred on her body and extremities. She was 80 kg and 154 cm tall. She had been used oral metformin hydrochloride 1000 mg/day because of DM. The physical examination revealed xerosis cutis and excoriations. In laboratory findings, we determined mild anemia because hemoglobin (Hgb) was 11 g/dL, hematocrite was 34.3%, mean cell Hgb (MCH) was 26.6 pg. Creatinine was 1 mg/dL, this value



Address for Correspondence: Melis Gönülal MD, University of Health Sciences Turkey, Izmir Tepecik Training and Research Hospital, Clinic of Dermatology, Izmir, Turkey

Phone: +90 506 888 95 69 **E-mail:** drmelis@gmail.com **ORCID ID:** orcid.org/0000-0002-6042-656X

Received: 22.11.2020 **Accepted:** 28.01.2021

©Copyright 2021 by the Society of Academy of Cosmetology and Dermatology / Journal of the Turkish Academy of Dermatology published by Galenos Publishing House.

was slightly above normal. All hepatitis makers were negative. Total IgE, sedimentation, vitamine B12, thyroid stimulating hormone and urine test were normal. Methylprednisolone aceponate lotion and bilastine tablet were recommended twice a day. The patient was examined again after three months and we observed urticaria like papules-plaques on her body. Omalizumab treatment was begun to patient 300 mg once a month and antihistamine medication was continued. Mometasone furoate cream prescribed instead of methylprednisolone aceponate lotion. After one month, cyclosporine was begun to patient 200 mg a day because pruritus continued severe, but the values of urea, creatinine, total cholesterol, low density lipoprotein, triglyceride, blood potassium increased to 52.8 mg/dL, 1.12 mg/dL, 283 mg/dL, 166 mg/dL, 171 mg/dL, 5.45 mmol/L respectively and value of magnesium decreased to 1.5 mg/dL Therefore cyclosporine treatment was stopped. Omalizumab treatment at 300 mg a month continued for three months after that due to unresponsiveness omalizumab injections were started at 300 mg every two weeks and clinical response was received. But then pruritus of the patient relapsed, totally after 11 doses, omalizumab was stopped. On physical examination, we noticed small vesicles on her body and took a biopsy from the patient (Figure 1). The result of the biopsy was determined as BP. In the biopsy report, linear accumulation of C3 and intermittent accumulation of IgG was determined at dermoepidermal junction. Accumulation of IgM, C1q, IgA and fibrinogen wasn't observed. The patient was referred to the internal medicine outpatient clinic to exclude malignancy. As a result of examinations, no malignancy was detected in the case. As medication, oral methylprednisolone at a dose of 48 mg/day, azathioprine at a dose of 150 mg/day, levocetirizine at a dose of 10 mg/day and topical steroid cream were begun for her, but

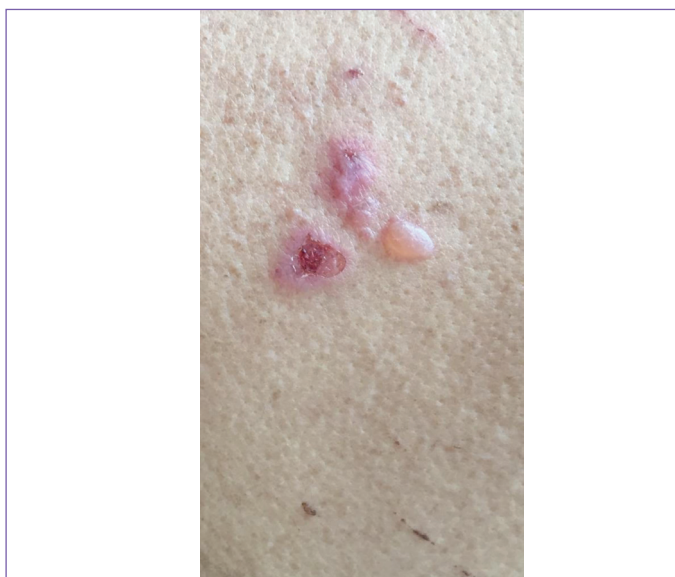

Figure 1. Intact bullae

methylprednisolone was stopped after 15 days because the patient developed insulin dependent DM, accordingly azathioprine was stopped because of high liver enzyme levels. Tetracycline tablet 500 mg dialy was started but after one month the patient complained of severe nausea and we had to stop tetracycline treatment, too. Extensive vesicles and bullaes became on her body (Figure 2). We didn't think BP due to drugs, because when metformin had been stopped and switched to insulin, BP of the case continued. Intravenous Ig (IVIG) treatment was started for the patient whose laboratory findings were normal except Hgb level of 10.6 gr/dL. After 6 doses of IVIG, the patient healed completely, there were no pruritus and no skin findings but after two months pruritus, vesicles and bullaes came back. Rituximab at a dose of 500 mg was given to the patient two weeks apart but clinical response wasn't received. Tetracycline tablet 500 mg daily and nicotinamide ampul 12 mg weekly were started in addition to the current treatment of the patient and nausea didn't occurred. Now our patient is in the second month of tetracycline and nicotinamide treatment and she is in remission (Figure 3). Accordingly she took 10 doses of IVIG but

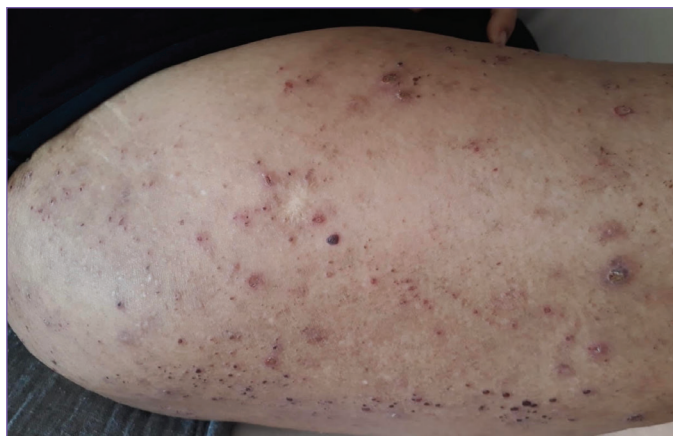

Figure 2. Excoriations, erosions, crusts

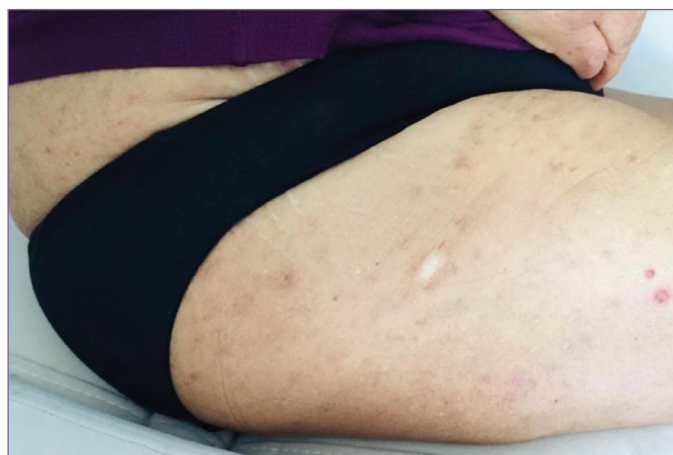


Figure 3. Healed lesions

because of Coronavirus disease-19 pandemic we couldn't continue IVIG treatment. We learned in our phone call that she was well and there was minimal pruritus. We continue now for her the treatments of tetracycline and nicotinamide.

Discussion

There are different treatment models for BP. According to BP diagnostic treatment guide, there are oral corticosteroids on first step for generalise form of disease. Azathioprine, mycophenolate mofetil, tetracycline and nicotinamide, methotrexate, chlorambucil take part on second step of treatment. For resistant cases, rituximab, omalizumab, IVIG, immunoadsorption, plasma exchange, cyclophosphamide are recommended on third step as alternative treatment or initial treatment [4].

Initially, our patient had complaints like urticaria and over time on physical examinations we saw urticaria like papules and plaques on her body. Therefore we recommended oral antihistamines and omalizumab treatment to our patient. Omalizumab took part in the treatment of BP and elevated IgE levels and/or eosinophilia are the important factors to recommend this antibody in BP. When we evaluate the mechanism of IgE in BP, IgE connect the free ectodomain of collagen XVII, which include the NC16A domain, to IgE autoantibodies bound to FcεRI expressed on mast cells and eosinophils. This binding stimulate degranulation and started an inflammatory process. In addition, IgE binds to the ectodomain NC16A located in the basal aspect of basal keratinocytes. Omalizumab obstructs the binding of IgE to these receptors [5,6]. Maybe omalizumab could be effective and vesicles, bullae couldn't appear in time. If it was like this, we could follow her as an urticaria patient and couldn't diagnose BP.

In time, because we observed vesicles on examination, we took biopsy and could diagnose BP. We applied the first step treatment for our patient but then stopped oral corticosteroid because she developed insulin resistant DM. When the patient didn't response to second step of treatment, we switched to tertiary care.

IVIG is an other alternative, safe and effective treatment model for BP. IVIG consists mainly of IgG1 and IgG2. Numerous mechanisms have been reported to explain the immunomodulatory effects of IVIG. To summarize, these proposed modes of action include saturation of the IgG protective neonatal FcR receptor (FcRn), neutralization of autoantibodies by anti-idiotypic antibodies, neutralization of cytokines or modulation of cytokine production, attenuation of complement-mediated tissue damage, modulation of functions of Fc receptors, and modulation of effector functions of T, B, and dendritic cells [7]. In literature, there are patients healed with IVIG but sometimes patients can be resistant to IVIG treatment as in our patient.

Rituximab is a chimeric anti-CD20 monoclonal antibody and an alternative treatment for recalcitrant BP. In Polansky et al.'s [8] study 15 of 20 patients with BP treated with rituximab (75%) achieved durable remission, with 5 patients requiring adjuvant therapy, 7 receiving minimal therapies, and 3 no longer taking any medications. Additionally, 9 patients were no longer taking prednisone at their last visit, suggesting a steroid-sparing benefit to rituximab therapy. Our case was resistant to rituximab.

Dupilumab, targeting interleukin-4 receptor alpha (IL4Rα), is a novel treatment for refractory BP. In recent reports, dupilumab has been successfully used off-label to treat a variety of pruritic disorders, including chronic spontaneous urticaria, anal and genital itch, allergic contact dermatitis, and prurigo nodularis [9]. Dupilumab isn't available in Turkey. If the disease of our case relapses, we can think to plan dupilumab for her with the approval of Turkish ministry of health.

BP can be confused with chronic idiopathic urticaria or other skin diseases like atopic dermatitis. Definitive diagnosis is made by pathology. Rarely, this disease can be refractory. There are different treatment models for resistant type of BP. We used combined last step treatment regimens for our case and achieved to treat her. We think that our case report will contribute to literature because such difficult, rare cases may appear to clinicians at any time and our case may be a guide for clinicians.

Ethics

Informed Consent: Consent form was filled out by all participants.

Peer-review: Internally peer-reviewed.

Authorship Contributions

Surgical and Medical Practices: M.G., D.D.B., Concept: M.G., D.D.B., Design: M.G., D.D.B., Data Collection or Processing: M.G., D.D.B., Analysis or Interpretation: M.G., D.D.B., Literature Search: M.G., D.D.B., Writing: M.G., D.D.B.

Conflict of Interest: No conflict of interest was declared by the authors.

Financial Disclosure: The authors declared that this study received no financial support.

References

1. Liu Y, Wang Y, Chen X, Jin H, Li L. Factors associated with the activity and severity of bullous pemphigoid: a review. *Ann Med* 2020;52:55-62.
2. Bağcı IS, Horváth ON, Ruzicka T, Sárdy M. Bullous pemphigoid. *Autoimmun Rev* 2017;16:445-455.
3. Zhao CY, Murrell DF. Outcome measures for autoimmune blistering diseases. *J Dermatol* 2015;42:31-36.
4. Feliciani C, Joly P, Jonkman MF, Zambruno G, Zillikens D, Ioannides D, Kowalewski C, Jedlickova H, Kárpáti S, Marinovic B, Mimouni D, Uzun S, Yayli S, Hertl M, Borradori L. Management of bullous pemphigoid: the European

- Dermatology Forum consensus in collaboration with the European Academy of Dermatology and Venereology. *Br J Dermatol* 2015;172:867-877.
5. Vico-Alonso C, Calleja-Algarra A, Aragón-Miguel R, Sánchez-Velázquez A, Velasco-Tamariz V, Ortiz-Romero PL, Monsálvez-Honrubia V. Omalizumab as an alternative therapeutic tool in the treatment of bullous pemphigoid: A case report. *Dermatol Ther* 2019;32:12829.
 6. Ujiie H. IgE autoantibodies in bullous pemphigoid: supporting role, or leading player? *J Dermatol Sci* 2015;78:5-10.
 7. Li N, Culton D, Diaz LA, Liu Z. Modes of Action of Intravenous Immunoglobulin in Bullous Pemphigoid. *J Invest Dermatol* 2018;138:1249-1251.
 8. Polansky M, Eisenstadt R, DeGrazia T, Zhao X, Liu Y, Feldman R. Rituximab therapy in patients with bullous pemphigoid: A retrospective study of 20 patients. *J Am Acad Dermatol* 2019;81:179-186.
 9. Seidman JS, Eichenfield DZ, Orme CM. Dupilumab for bullous pemphigoid with intractable pruritus. *Dermatol Online J* 2019;25:13030/qt25q9w6r9.