

Case of Eosinophilic Cellulitis Diagnosed 20 Years After Onset and Treated with Doxycycline Therapy

Müzeyyen Gönül,* MD, Seray Külçü Çakmak, MD, Nimet Özcan, MD, Ülker Gül, MD, Murat Demiriz,¹ MD

Address: SB Ankara Numune Education and Research Hospital, Dermatology Clinic, Sıhhiye, Ankara, Turkey; ¹Gülhane Military Medical Academy, Department of Microbiology, Ankara, Turkey.

E-mail: muzeyyengonul@yahoo.com

* Corresponding Author: Müzeyyen Gönül Yıldızevler Mah. 742. Sok. Aykon Park Sitesi A Blok No:3/3, Çankaya, Ankara, Turkey.

Published:

J Turk Acad Dermatol 2012; **6** (4): 1264c2

This article is available from: <http://www.jtad.org/2012/4/jtad1264c2.pdf>

Key Words: Eosinophilic cellulitis, Wells' syndrome, drug

Abstract

Observation: Eosinophilic cellulitis (Wells' syndrome) is rare and recurrent inflammatory dermatosis with uncertain etiopathogenesis, variable cutaneous lesions and nonspecific histopathological findings. The diagnosis can be made with a combination of typical clinical appearance and course and histopathological findings. The diagnosis may be difficult because of its rarity. We present a case of eosinophilic cellulitis diagnosed 20 years after onset. Diabetes mellitus and/or antidiabetic antihypertensive drugs might be the trigger factors in the present case and doxycycline may be an alternative therapy for eosinophilic cellulitis.

Introduction

Eosinophilic cellulitis (Wells' syndrome) is an uncommon, recurrent inflammatory dermatosis characterized by variable cutaneous lesions with nonspecific histopathological findings [1]. Eosinophilic cellulitis presents clinically with an acute pruritic dermatitis resembling cellulitis [2, 3, 4]. Papules, plaques, papulonodules, urticaria-like, papulovesicular, bullous, annular granuloma-like, fixed drug eruption like lesions have been described in some cases [1, 5, 6, 7]. The disease might be under diagnosed because of its polymorphic presentation especially when the histopathologic examination does not show flame figures.

We present a case whose diagnosis could not be made for 20 years.

Case Report

A 74-year-old woman presented with the complaint of pruritic, edematous, erythematous eruption on her trunk, gluteal region and anterior and lateral surfaces of thighs. The patient's lesions had first occurred 20 years ago and recurred periodically with itching and burning since then. She defined that new lesions occurred on any region of the skin while the lesions regressed spontaneously within one month. The patient did not recall any history of insect bite or trauma. Previously, she had attended to dermatologists repeatedly and she had been diagnosed clinically as urticaria, urticarial vasculitis, insect bite and contact dermatitis. It was learned that previous histopathological examinations of her lesions produced superficial perivascular dermatitis with eosinophilic infiltration and were not consistent with presumed diagnoses. She had also diabetes mellitus, hypertension for 20 years. Her skin lesions had first occurred several

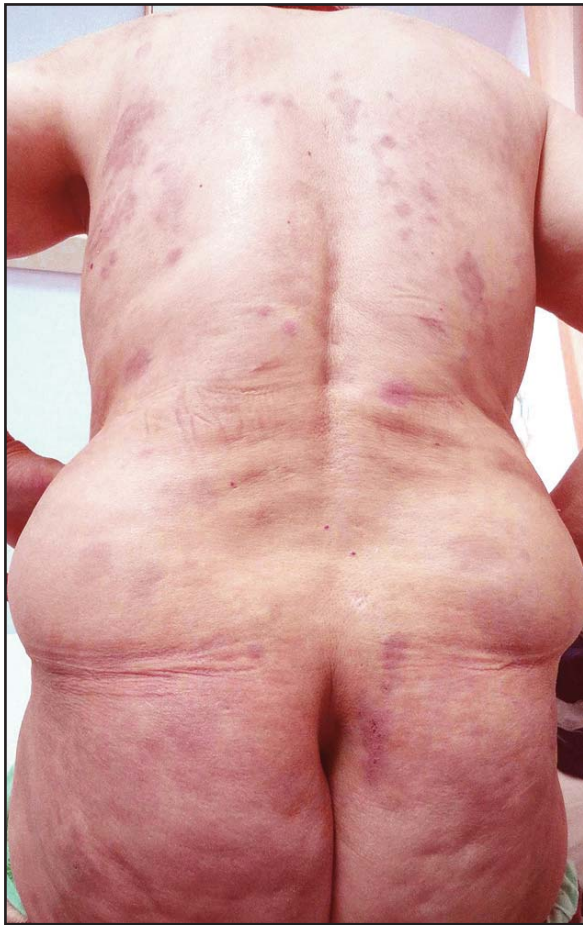

Figure 1. Indurated red/bluish papules and various sized plaques. Some of them are annular shaped with erythematous indurated borders and bluish hue on the centers

months after the onset of metformin, olmesartan medoxomil and hidroclorotiazid therapies. Her other medications included insulin and lansopra-

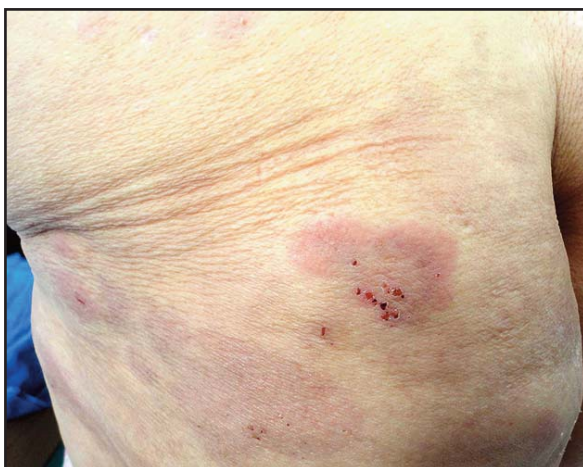

Figure 3. Closer appearance of the annular lesion and bluish macules on her gluteas

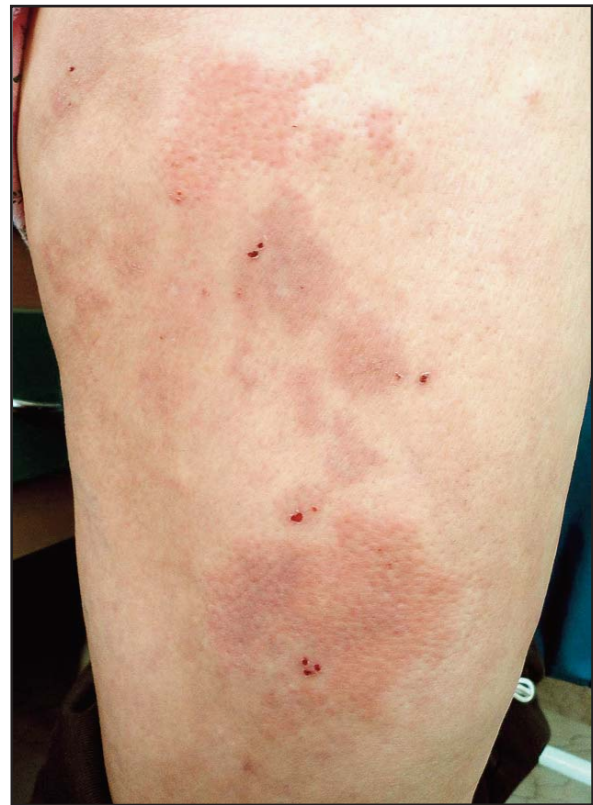

Figure 2. Closer appearance of the annular and plaques lesions on the lower extremity

zole for DM and antral gastritis which she had started using 3 years before she applied to us.

Clinical examination of skin revealed nearly symmetrical indurated red/bluish papules and various sized plaques. Some of the plaques were annular shaped with erythematous indurated borders and bluish hue on the centers (**Figures 1, 2, 3**). Excoriations were observed on some lesions. Old lesions appeared as bluish macules of patches.

Histopathological examination of two biopsy materials obtained from different lesions showed perivascular and interstitial dermatitis composed predominantly of eosinophil leukocytes (**Figures 4, 5**). The patient was diagnosed as eosinophilic cellulitis with clinic appearance, past medical history of the lesions and histopathological examination.

Laboratory investigations including serum immunoglobulin (Ig) E level, antinuclear antibodies, stool analysis for parasites in addition to routine tests revealed normal results. Blood glucose level was labile because of her inordinate insulin usage. Viral markers for viral hepatitis and HIV infection were negative. Abdominal ultrasound and X-ray were within normal limits.

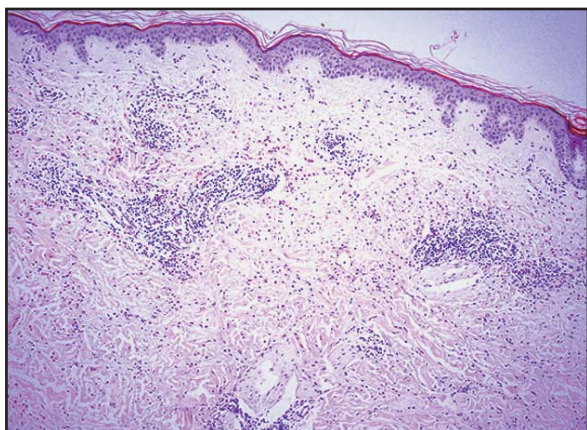


Figure 4. Perivascular and interstitial dermatitis composed of predominantly eosinophil leukocytes (H&E,x 50)

Oral corticosteroid therapy was not administered because of the lability of blood glucose levels and antihistamine therapies were not successful. Metformin, olmesartan medoxomil and hidroclorotiazid therapies were changed and doxycycline therapy was administered (100 mg/day for 1 month) and her lesions gradually improved.

Discussion

Underlying etiopathogenesis of eosinophilic cellulitis is unknown. Reported trigger factors includes insect bites, cutaneous viral, fungal and parasitic infections, medications, vaccinations, eczema, autoimmune diseases, diabetes, carcinomas, leukemia and other myeloproliferative disorders. Eosinophilic cellulitis has been thought to be a hypersensitivity response to these trigger factors [3, 5, 7, 8]. In the present case, diabetes mellitus might be an endogenous stimulus for eosinophilic cellulitis because their onset time was nearly concurrent. Also, antidiabetic and antihypertensive medications might be exogeneous stimuli although associations with metformin, olmesartan medoxomil or hidroclorotiazid have not been reported eosinophilic cellulitis previously.

Eosinophilic cellulitis develops with recurrent episodes of prodromal itching and burning followed by rapid development of red indurated plaques resembling bacterial cellulitis. Over a few weeks the lesions become indurated, with blue-green discoloration. The eruption resolves within 1-2 months without scarring. Reticulate pigmentation and scarring alopecia have been reported [3, 5, 6, 9]. The common sites of occurrence, in decrea-

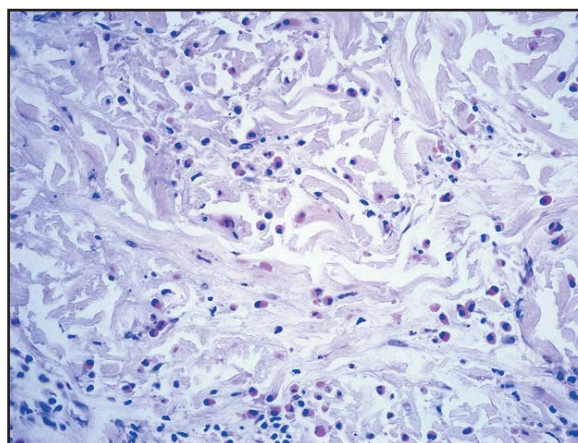


Figure 5. Note grouped eosinophils between collagen fibrils (H&E x 200)

sing order of frequency, are the legs, trunk, arms, face, neck and scalp [5]. Our case had concurrent papules, plaques, annular granuloma-like lesions and blue-green discoloration and they were localized on the trunk and extremities.

Histologically, in the acute stage, there is a dense dermal infiltrate of eosinophils and dermal oedema. Then, dermal histiocytes and eosinophils infiltrate connective tissue bundles coated with eosinophilic debris to form flame figures [1, 5, 6]. Flame figures are seen in only about 50% of the cases [1]. The regressive stage shows a gradual disappearance of eosinophils with persistence of histiocytes and appearance of giant cells around collagen deposits without vasculitis [1, 5, 9]. Histopathological picture is not pathognomonic for eosinophilic cellulitis similar picture may be seen in other inflammatory dermatoses such as bullous pemphigoid, eczema and prurigo [5]. Because of this, diagnosis of eosinophilic cellulitis is made with a combination of typical clinical appearance and course and histopathological findings [1, 6].

Histopathological examination in eosinophilic cellulitis is very important but when flame figures are not seen in histopathological examination as in our case especially if eosinophilic cellulitis is not kept in mind the diagnosis of the disease gets difficult. This complexity raises the idea that eosinophilic cellulitis might be occurring more than known and the diagnosis might be missing. Our case supports this idea. So, we want to stress that careful anamnesis and clinical examination

are very important as well as histopathological examination.

Blood eosinophilia was found in approximately 50% of cases and the level of eosinophils may fluctuate with the course of disease [1, 9]. Our case did not have blood eosinophilia.

Standard treatment for eosinophilic cellulitis is oral steroids. Topical steroids, antihistamines, dapsone, cyclosporine, azathioprine, griseofulvin, doxycycline, minocycline and interferon- α 2a have been reported to be effective [3, 4, 5, 9]. Doxycycline was administered only in one patient for eosinophilic cellulitis previously and it was used 100 mg in day for 10 days [2]. We administered doxycycline 100mg/day for a longer time because the lesions recurred after its cessation. We think that doxycycline might have been useful because its effects of antiinflammatory and limited occurrence of granuloma.

Consequently, eosinophilic cellulitis is a disease of unknown etiology and showed diagnostic challenges. We think that the present case may provide contribution in several topics. It shows that keeping in mind the diagnosis of eosinophilic cellulitis, careful anamnesis and clinical examination are important in the diagnosis because of the missing of diagnosis for 20 years. Diabetes mellitus and/or antidiabetic and antihypertensive medications might be trigger factors for eosinophilic cellulitis. Doxycycline may be a good and safe alternative therapy especially

in the patients whom oral steroid use is not appropriate. Longer administration periods might be needed in the patients whose lesions show frequent recurrences.

References

1. Caputo R, Marzano AV, Vezzoli P, Lunardon L. Wells syndrome in adults and children: a report of 19 cases. Arch Dermatol 2006; 142: 1157-1161. PMID: 16983003
2. Moossavi M, Mehregan DR. Wells' syndrome: a clinical and histopathologic review of seven cases. Int J Dermatol 2003; 42: 62-67. PMID: 12581147
3. Ladoyanni E, Vlachou C, Thushara R, Snead D. A patient with Wells' syndrome. Clin Exp Dermatol 2010; 35: e3-4. PMID: 20500167
4. Zindancı I, Kocatürk E, Can B, Büyükbabani N, Kavalı M. A Case of eosinophilic cellulitis (Wells' Syndrome). Türkiye Klinikleri J Dermatol 2005;15: 156-159.
5. Ling TC, Antony F, Holden CA, Al-Dawoud A, Coulson IH. Two cases of bullous eosinophilic cellulitis. Br J Dermatol 2002; 146: 160-161. PMID: 11841390
6. Holme SA, McHenry P. Nodular presentation of eosinophilic cellulitis (Wells'syndrome). Clin Exp Dermatol 2001; 26: 677-679. PMID:11722455
7. Ghislain PD, Van Eeckhout P. Eosinophilic cellulitis of papulonodular presentation (Wells' syndrome). J Eur Acad Dermatol Venereol 2005; 19: 226-227. PubMed PMID:15752298
8. Moustafa Hussein WH, Barzaga R, Seifi A, Shinde A, Rodriguez W. Punch biopsy in Wells syndrome. South Med J 2009; 102: 775. PMID: 19488009
9. Rousseau L, Beylot-Barry M, Vergier B, Doutre MS, Beylot C. Guess what? Wells'syndrome. Eur J Dermatol 1999; 9: 61-62. PMID: 10094595