

Case Report

A Case of Psoriasis Complicated with Systemic Lupus Erythematosus

Aycan Özden Sezgin, MD, Bengü Gerçeker Türk, MD, İlgen Ertam, MD, Figen Yargucu Zihni,¹ MD, Ali Can Kazandı, MD, İdil Ünal, MD

Address: Ege University Medical Faculty, Department of Dermatology, ¹Division of Rheumatology, Department of Internal Medicine, Izmir/Türkiye

E-mail: aycanozdemir@yahoo.com

* Corresponding Author: Aycan Özden Sezgin, Ege University Medical Faculty Department of Dermatology 35040 Bornova-Izmir, Turkey

Published:

J Turk Acad Dermatol 2010; 4 (4): 04403c

This article is available from: <http://www.jotad.org/2010/4/jtad04403c.pdf>

Key Words: psoriasis, lupus erythematosus

Abstract

Observations: Psoriasis is a chronic, inflammatory skin disease. Autoimmune diseases such as Hashimoto thyroiditis, autoimmune hemolytic anemia and Sjögren syndrome have been reported to accompany psoriasis. However, association of "psoriasis and systemic lupus erythematosus" is very rare. Here, we report a 45-year-old woman with psoriasis vulgaris complicated with systemic lupus erythematosus.

Introduction

Psoriasis vulgaris and lupus erythematosus (LE) are relatively common diseases in the population but their association is rare. LE complicating psoriasis has seldom been reported in the literature [1]. Here, we report development of systemic lupus erythematosus (SLE) in a psoriatic patient.

Case Report

A 45-year-old woman was admitted to us with generalized psoriasis all over the body. The patient had been diagnosed as "psoriasis and psoriatic arthritis" for 12 years. The medical history revealed hypertension, episodes of depression, two first trimester abortions, photosensitivity and intermittent leflunomide use (100 mg tablet/day) of two years for psoriatic arthritis. The history of psoriasis was present in her father. The previous medication for psoriasis had been acitretin (35 mg/day) until thrombocytopenia had been detected during the

follow-up. Therefore, acitretin had been thought to be the trigger of thrombocytopenia and stopped. After then, low dose systemic steroid (prednisolone 10 mg/day) for two months had been started by an internist for arthralgia.

On dermatological examination, erythematous, scaling plaques on the scalp, trunk and both limbs were observed (Figure 1, Figure 2). Psoriasis area and severity index (PASI) was 16,6. Histopathology of the skin biopsy was consistent with "psoriasis vulgaris" (Figure 3). Immunological tests revealed ANA (1/320 granular) positivity, elevated anti Ro, anti-cardiolipin IgG and anti-β2 glycoprotein IgG levels. Based on the clinical and laboratory findings the patient was diagnosed as psoriasis as well as SLE and anti-phospholipid antibody syndrome (APAS). The patient's concurrent steroid treatment was maintained since the anti-malarial treatment recommended by the rheumatologists might worsen psoriasis. The patient was commenced on azathioprine (100 mg/day), acetyl salicylic acid (300 mg/day) for SLE and APAS, and on acitretin for psoriasis (35 mg/day). On her fol-

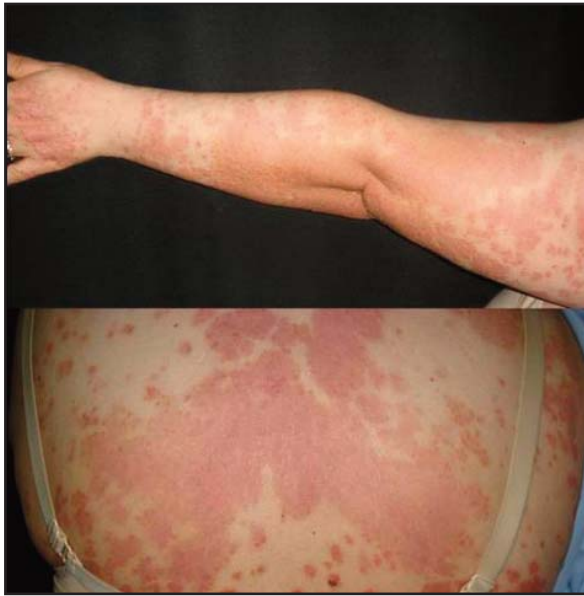

Figure 1. Erythematous plaques with limited silvery scale on arm and trunk

low-up, psoriatic lesions resolved and thrombocyte count approached to normal limits.

Discussion

SLE and discoid LE may complicate psoriasis [1, 2, 3]. Among them, presence of SLE is much rarer than discoid LE. LE is estimated to be found in 0.0023% of 9500 psoriatic patients [1]. The underlying autoimmune mechanism of this association is still unknown. Although, anti-Ro positivity has been proposed as a specific serological marker for the association of psoriasis and LE [4], there are contrary reports of some psoriatic patients complicated by SLE with normal anti-Ro antibody levels [5,6]. Also, anti-Ro may be positive in some psoriasis patients without such

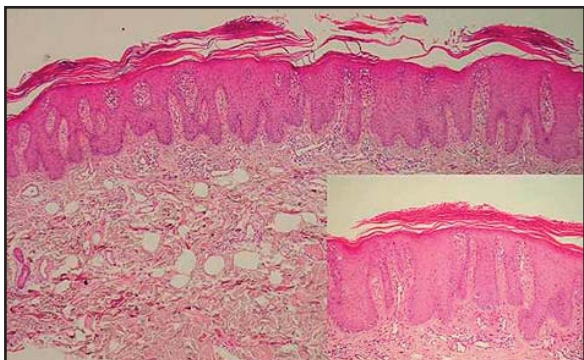


Figure 3. Epidermal regular psoriasiform hyperplasia in the epidermis and parakeratosis with Munro's microabscesses

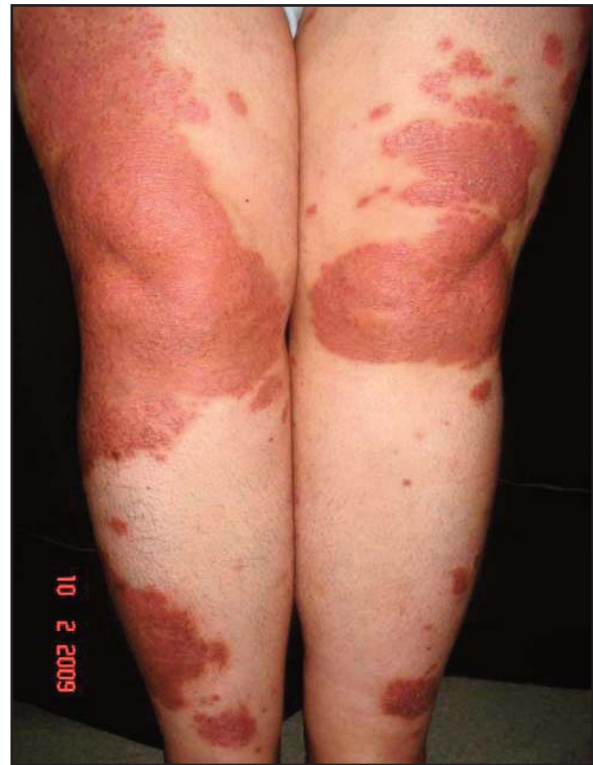

Figure 2. Erythematous plaques with limited silvery scale on legs

an association [7]. In our patient, ANA was found to be as 1/320 together with an elevated anti-Ro antibody level. Besides the ANA positivity, photosensitivity, presence of anti-cardiolipins, thrombocytopenia established the diagnosis of SLE in our patient according to the ARA criteria [8].

The association of SLE and psoriasis may lead difficulties during the therapeutic processes. Topical and systemic steroids, anti-malarial agents, acitretin, methotrexate, azathioprine, cyclosporine, dapsone and phototherapy (PUVA, UVB) have been used in patients with psoriasis and LE [1, 2, 3]. Anti-malarial agents and systemic steroids that are commonly used for SLE are among the drugs which are contraindicated for psoriasis. Phototherapy, commonly used in treatment of psoriasis, is not a good option as it may exacerbate LE. Biological agents may trigger a lupus-like syndrome as well as they may exacerbate the disease process. In our patient, methotrexate was not considered because of the thrombocytopenia and cyclosporine was not allowed because of hypertension. As a consequence, the patient was treated with acitretin for psoriasis; azathioprine (100

mg/day), acetyl salicylic acid (300 mg/day) for SLE.

As a conclusion, development of thrombocytopenia independently from treatment side effects may be a clue for an underlying SLE in a psoriatic patient. Because of the limited number of psoriatic patients complicated by SLE, management of this condition may be challenging for the physician.

References

1. Zalla MJ, Muller SA. The coexistence of psoriasis with lupus erythematosus and other photosensitive disorders. *Acta Derm Venereol Suppl* 1996; 195: 1-15. PMID: 8721520
2. Wielosz E, Majdan M, Zychowska I, Jeleniewicz R. Coexistence of five autoimmune diseases: diagnostic and therapeutic difficulties. *Rheumatol Int* 2008; 28: 919-923. PMID: 18320193
3. Millns JL, Muller SA. The coexistence of psoriasis and lupus erythematosus. An analysis of 27 cases. *Arch Dermatol* 1980; 116: 658-663. PMID: 7377802
4. Kulick KB, Mogavero H Jr, Provost TT, Reichlin M. Serologic studies in patients with lupus erythematosus and psoriasis. *J Am Acad Dermatol* 1983; 8: 631-634. PMID: 6602815
5. Baselga E, Puig L, Llobet J, Musulén E, de Moragas JM. Linear psoriasis associated with systemic lupus erythematosus. *J Am Acad Dermatol* 1994; 30: 130-133. PMID: 8277015
6. Hays SB, Camisa C, Luzar MJ. The coexistence of systemic lupus erythematosus and psoriasis. *J Am Acad Dermatol* 1984; 10: 619-622. PMID: 6425367
7. Janjumratsang P, Phainupong D, Chanjanakijskul S, Roongphibulsopit P. Positive direct immunofluorescence and autoantibody profiles in psoriasis patients. *J Dermatol* 2008; 35: 508-513. PMID: 18789071
8. Tan EM, Cohen AS, Fries JF, et al. The 1982 revised criteria for the classification of systemic lupus erythematosus. *Arthritis Rheum* 1982; 25: 1271-1277. PMID: 7138600