

Review

## Art in Turkish Dermatology

Yalçın Tüzün,\* MD

Address:

Professor of Dermatology, Cerrahpaşa Medical Faculty, Istanbul University, Fatih, Istanbul, 34098 Turkey

E-mail: yalcintuzun@yahoo.com

\* Corresponding author: Yalçın Tüzün, MD, Cerrahpaşa Medical Faculty, Istanbul University, Fatih, Istanbul, 34098 Turkey

Published:

*J Turk Acad Dermatol* 2007;1 (2): 71201r

This article is available from: <http://www.jtad.org/2007/2/jtad71201r.pdf>

**Key Words:** Art, Turkish dermatology, dermatology

### Abstract

**Background:** Iconography plays a crucial role in the field of dermatology unlike other specialties. The collection composed of portraits, pictures, cartoons, wax moulds and miniatures represents the social and historical aspects of Turkish dermatology. The theme is mostly the definition of diseases and interventions. The artworks, unlike the counterparts in western countries are only created by physicians. Currently this collection is exhibited in 3 different museums in Istanbul University and Municipal Medical Center of Istanbul and draws the attention of paramedical visitors interested in medical culture and history as well as dermatologists.

Iconography plays a crucial role in the field of dermatology unlike other specialties. The representation of a skin disease is rehearsed by 3 major characters: the patient, the physician and the artist who has devoted his skills to reality rather than beauty. The collection composed of portraits, pictures, cartoons, wax moulds and miniatures represents the social and historical aspects of Turkish dermatology. The theme is mostly the definition of diseases and interventions. Numerous masterpieces have gained life during a fruitful period from the beginning of 19<sup>th</sup> century until recent years. Among these one can find artwork created through occidental techniques, such as wax moulds and also techniques that belong exclusively to the artists of Ottoman Empire, namely the miniatures. The artworks, unlike the counterparts in western countries are only created by physicians. Art describing medical conditions and scenes have not drawn the attention of



classical Turkish artists. Currently this collection is exhibited in 3 different museums in Istanbul University and Municipal Medical Center of Istanbul and draws the attention of paramedical visitors interested in medical culture and history as well as dermatologists. Although far from being appealing

**Figure 1.** An ancient Turkish physician



Figure 2. Ambulance

to the eyes, wax moulds are admired for the quality of the lesions and features that give the impression of actual patients about to open their eyes. They reflect the superior cultural level of Turkish dermatology.

In the figures below, some examples are seen.



Figure 3. This miniature is a representation of a consultation among physicians



Figure 4. Miniature is a technique of two-dimensional pictures lacking perspective that reflects the oriental point of view



Figure 5. These works of art of heroic physicians that could be named as "backstage performers" have served as educational tools in those times when photography was routinely unavailable for the practicing dermatologist



**Figure 7.** Saint Mary and Jesus Christ [1]


The following figures are miniatures of medical practices in the Ottoman period.



**Figure 9.** This miniature illustrates a female patient with lepromatous nodules on her feet



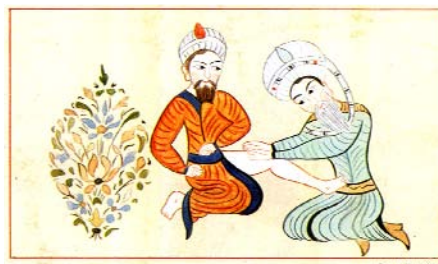**Figure 8.** This miniature depicts an interventional setting about the drainage of hydradenitis suppurativa lesions [2]



**Figure 10.** An interesting approach to lepromatous lesions is pictured: cauterization [2]



**Figure 11.** Creating a fistula on the nose of a patient with rhinophyma [2]

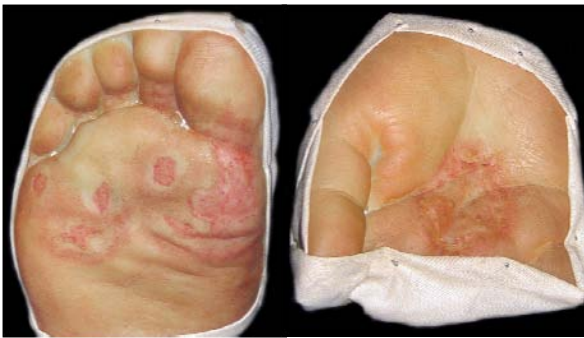

**Figure 12.** An interventional treatment to sinuses by evacuation is illustrated

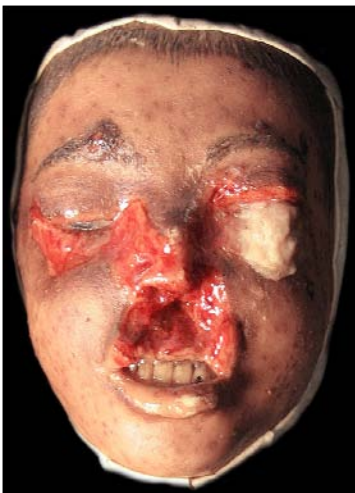

**Figure 13.** The humble nature of the physician is easily judged by the appearance. The similarity in vesture and the level of placement in picture of both characters would not give way to any hint of haughtiness, however a long and gray beard is a representative of wisdom and sapience [2].

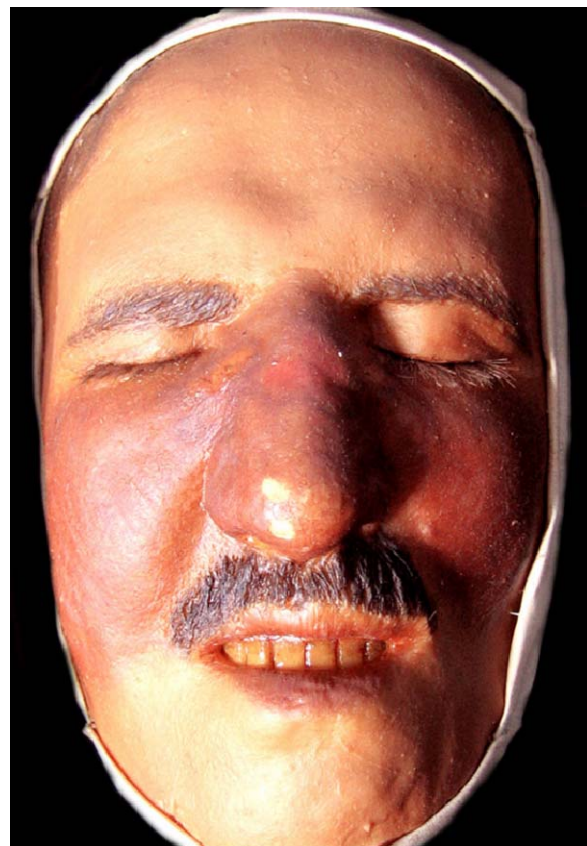The following figures are wax models of some dermatological conditions.



**Figure 14.** Tinea pedis et manum



**Figure 15.** This face, full of various lesions is a good representative of unfortunate patients with xeroderma pigmentosum




**Figure 16.** Although one can not see the expression in the eyes, the agony on this face of a man with erysipelas is beyond that of an inanimate object can reflect


The following figures are oil paints of some diseases.



**Figure 17.** This picture enables the current dermatologists to imagine a skin eruption that does not exist any more: Variola



**Figure 18.** This work depicts the eruption of secondary syphilis



**Figure 19.** A very succesful illustration of the faint macules of syphilitic roseola

## References

1. Falname, Topkapi Museum 17th Century.
2. Ahmet b. Zünbul-el Mahalli el-Munecim er-Remmal. The author of the "Havi Acaibi'l-mahlukat ve Cami'u Gara'ibi'l-Mevcudat". Topkapi Museum, Book No. 1638. Before 1572.