

Clinico-pathological Study of Pretibial Region Changes in Graves' Disease

Projna Biswas,^{1*} MD, Subhankar Chaudhury,² MD, Sumit Sen,¹ MD, Uttara Chatterjee,¹ MD, Atul Jain,¹ MD, Anusree Gangopadhy,¹ MD, Ayan Samanta,¹ MD

Address: ¹Department of Dermatology, ²Department of Endocrinology Institute of Post Graduate Medical Education and Research Kolkata West Bengal, INDIA.

E-mail: drprojna@gmail.com

* Corresponding Author: Projna Biswas, MD, Department of Dermatology Institute of Post Graduate Medical Education and Research Kolkata West Bengal INDIA.

Published:

J Turk Acad Dermatol 2014; **8 (4)**: 1484a2.

This article is available from: <http://www.jtad.org/2014/4/jtad1484a2.pdf>

Key Words: Graves' disease, pretibial myxedema, exophthalmos

Abstract

Background: Graves' disease which consists of goiter with excessive discharge of thyroid hormones also has important extra thyroid manifestation. Thyroid dermopathy (pretibial myxedema) is an autoimmune phenomenon of Graves' disease. In fact the extrathyroidal manifestations of this form of thyrotoxicosis are due to immunologically mediated activation of fibroblasts in the extraocular muscles and the skin, with accumulation of glycosaminoglycans, leading to trapping of water and edema. This study highlights the pretibial region changes under light microscopy in known Graves' disease patients.

Aims: The aims of this study are to evaluate the prevalence of pretibial myxedema in Graves' disease and to explore the histopathological features of the pretibial regions.

Materials and methods: This was an observational study. Thirty consecutive cases of Graves' disease diagnosed in the endocrinology department and subsequently attending the dermatology OPD of a tertiary care hospital were examined clinically and skin biopsy of the pretibial region was done. Specimens were examined under light microscopy.

Result: In our study we found 4 patients (13.3%) had frank pretibial myxedema. Among these only 1 patient (25%) had associated exophthalmos. About 12 cases (40%) of all Graves' disease patients had exophthalmos. The patient with overt pretibial changes was seen to be suffering with Graves' disease for more than 1 year. Histopathological examination of the area showed flat or atrophic epidermis with prominent dermal edema, separation and fibrosis of dermal collagen. We also found that about 8 patients (26.6%) of those who had Graves' disease for less than 1 year developed hyperkeratosis and mild fibrosis of dermis on histopathological examination. Both sexes were equally affected by pretibial myxedema (1:1). We also noticed that patients of frank pretibial myxedema had extremely high level of free T4 levels (148-470mg/dl).

Conclusion: Pretibial myxedema of Graves' disease is a late manifestation and associated with a very high level of circulating thyroid hormones. It was occasionally preceded by ophthalmopathy.

Introduction

Graves' disease is the commonest type of thyrotoxicosis accounting for 60-80% of the cases and consists of one or more of the fol-

lowing characteristics: goiter with hyperthyroidism, exophthalmos, thyroid dermopathy and acropachy [1]. Often such patients present to the physician with features of hyperthyroidism without any other apparent

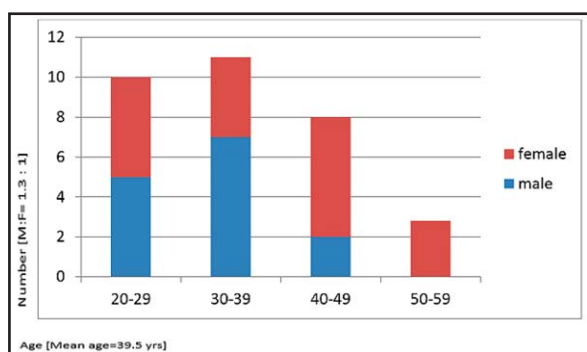


Figure 1. Demographical profile

clinical feature. At other times a proper examination of the extremities and the eyes are missed thus overlooking vital signs of pretibial myxedema and exophthalmos which would give important information about the disease. Finding of thickened skin over the lower legs often with non pitting edema is essential in the context of diagnosis of Graves' disease and may indicate advanced stage of the disease. A finding of this lesion can prompt the physician to institute early therapeutic measures against thyrotoxicosis.

Materials and Methods

This study was conducted in the Department of Dermatology of a tertiary care Hospital in Kolkata. This is an ongoing prospective study, and results of 1 year are being reported. All patients (from study date) fulfilling the inclusion criteria and attending the Endocrinology OPD and subsequently the Dermatology OPD will be included in the study. These patients are interviewed and examined clinically and a small punch biopsy taken for histopathological examination.

This is an observational cross sectional study. 30 patients examined and data obtained were recorded in a Proforma.

Inclusion criteria: Patients fulfilling the criteria of Graves' disease with or without clinical evidence of extrathyroid manifestation.

Exclusion criteria: Patients fulfilling the inclusion criteria but presenting some other lesion over pretibial region. A patient however could consent partly i.e. for providing history and clinical examination but unwilling to do skin biopsy.

Results

Out of 30 patients of Graves' disease 17 were male and 13 were female (1.3:1). Most of the

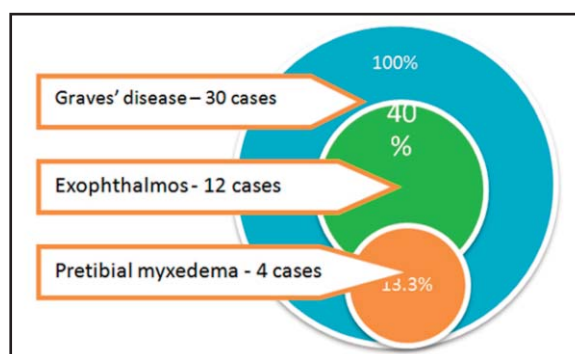


Figure 2. Prevalence

patients were middle aged adult, mean age was 39.5 years (**Figure 1**). Among the patients clinically evident pretibial myxedema were present in 13.3% cases and female to male ratio was 1:1. Development of clinically significant pretibial myxedema (found in 4 patients) is usually late and most patients developed more than 1 year after diagnosis of Graves' disease. But microscopical changes started to occur much earlier. About 26.6 % cases developed some changes in the pretibial region before 1 year of diagnosis of Graves' disease. Among all patients 16.67% cases had changes in their epidermis while dermal changes were found in 33.33% of cases (**Tables 1 and 2**). Those patients who had clinical thyroid dermopathy over pretibial region had very high level of T4 (148-470 mg/dl) and in contrast T3 were high in patients without that clinical finding (**Table 3**). 25% cases of frank pretibial myxedema patients were associated with exophthalmos (**Figure 2**).

Discussion

Thyroid dermopathy is generally known as pretibial myxedema though the immunologically mediated deposit of glycosaminoglycans may occur at sites other than pretibial region. The hypothesis of immunological factor is well known but other scientists have presented the reasoning that these lesions are the result of local factors superimposed on chronic low grade inflammation [2]. Thyroid dermopathy occurs in <5% of cases of Graves' disease [3]. In our study prevalence of pretibial myxedema is 13.3% of total Graves' disease patients. Male to female ratio in developing pretibial myxedema is 3.5:1 [4]. But in our present study we found it is 1:1. Though asymptomatic and having only cos-

Table 1. Histopathological Changes of Epidermis

Epidermal changes	No. of patients	% of patients
Hyperkeratosis	2	7%
Flat epidermis	2	7%
Atrophic	1	3.3%
Normal	25	83%

metic importance the lesions usually occur in late stage of the ailment often accompanied with severe ophthalmopathy [5]. Thyroid dermopathy typically develops 12 to 24 months after the diagnosis of thyrotoxicosis [6]. Pretibial myxedema can at times herald the onset of the disease and is known to occur in the absence of ophthalmopathy [7]. In our study we found patients having frank pretibial myxedema were asymptomatic and usually manifested later more than 1 year after diagnosis of Graves' disease. Also there was lesser association of ophthalmopathy with pretibial myxedema than documented (25%). Pretibial myxedema usually presents with brawny non edematous swelling on the lower legs typically known as 'orange skin appearance' but has also been reported to occur over the upper extremities [4]. Nodular and plaque forms can occur. Polypoidal type of this disorder is a rare variety, as is Elephantiasis Nostras Verrucosa which has been reported from our country [8]. This last type manifests as huge elongated mass over the lower part of the legs.

Where thyrotrophin and free thyroxin are the most used tests in invitro diagnosis of Graves' disease, tibial dermopathy mostly has been diagnosed clinically. No specific relation with level of thyroid hormones has been mentioned in the literature. In our study we found that patients who had clinical evidence of pretibial myxedema also had significantly eleva-

Table 3. Thyroid Profile of The Patients with Frank Pretibial Myxedema

No	Sex	Duration of disease (months)	T3(µg/dl) normal=0.14	T4(µg/dl) normal=8	TSH
1	Male	6	21	470	0.02
2	Female	24	7.6	248.4	0.02
3	Female	12	22.41	256.2	0.03
4	Male	48	0.94	148	7.5

Table 2. Histopathological Changes of Dermis

Dermal changes	No. of patient	% of patients
Dermal edema	3	10%
Hyalinization	3	10%
Fibrosis	4	13%
Normal	20	66.7%

ted level of thyrotropin. Histology has been used in some cases to confirm the diagnosis while pretibial ultrasound was used to diagnose this disorder in one other case [9]. On histopathology of the pretibial region we found epidermal changes in 16.67 % and dermal changes in 33.33% of cases of Graves' disease with or without clinical myxedema.

Topical potent Glucocorticoid application often under occlusion has been the main stay in treating this sort of edema though the beneficial effects of such therapy on long term remission of pretibial myxedema has been questioned in some studies [10]. We also treated our cases with potent topical steroid with appreciable clinical improvement.

Conclusion

This study shows pretibial myxedema or thyroid dermopathy is a late manifestation of Graves' disease (more than 1 year) with mean age 39.5 years with equal sex distribution. Pretibial myxedema is associated with high level of circulating thyroid hormone and occasionally not always preceded by ophthalmopathy.

References

1. Sauer P, Brandes B, Mahmarian RR. Lower extremity manifestations of Graves' disease. J Foot Ankle Surg 1995; 34: 489-497. PMID:8590885
2. Rapoport B, Alsabeh R, Aftergood D, McLachlan SM. Elephantiasic pretibial myxedema: insight into and a hypothesis regarding the pathogenesis of the extrathyroid manifestations of Graves' disease. Thyroid 2000; 10: 685-692. PMID:11014313.
3. Omohundro C, Dijkstra JW, Camisa C, Bergfeld WF. Early onset pretibial myxedema in the absence of ophthalmopathy: a morphologic evolution. Cutis. 1996; 58: 211-214. PMID:8886536
4. Fatourechi V, Pajouhi M, Fransway AF. Dermopathy of Graves disease (pretibial myxedema). Review of 150 cases. Medicine (Baltimore). 1994; 73: 1-7. PMID:8309359.

5. Prajapati VH, Mydlarski PR. Dermacase. Pretibial myxedema. *Can Fam Physician* 2008; 54: 357-369. PMID:18337527
6. Fatourechi V. Pretibial myxedema: pathophysiology and treatment options. *Am J Clin Dermatol* 2005; 6: 295-309. PMID:16252929.
7. Chiovato L, Barbesino G, Pinchera A. Graves Disease Endocrinology. 4th ed. Philadelphia: WB Saunders; 2001.
8. Kakati S, Doley B, Pal S, Deka UJ. Elephantiasis Nostri Verrucosa: a rare thyroid dermopathy in Graves' disease. *J Assoc Physicians India* 2005; 53: 571-572. PMID:16121817
9. Salvi M, De Chiara F, Gardini E, Minelli R, Bianconi L, Alinova A et al. Echographic diagnosis of pretibial myxedema in patients with autoimmune thyroid disease. *Eur J Endocrinol* 1994; 131: 113-119. PMID:8075779
10. Cox NH, Coulson IH. Systemic disease and the skin. In: Rook's textbook of dermatology. Burns T, Breathnach S, Cox N, Griffith C, eds. 8th ed. Singapore, Wiley-Blackwell; 2010; p.63.1-113.