

Lichen Striatus in Two Adults

Emine Ünal,^{1*} MD, İlknur Balta,² MD, Özlem Bozkurt,³ MD, Gülüşan Ergül,³ MD

Address: ¹Department of Dermatology, Yenimahalle State Hospital, ²Department of Dermatology, Keçören Research and Training Hospital, ³Department of Pathology, Yenimahalle State Hospital, Ankara, Turkey

E-mail: eminesu83@gmail.com

* Corresponding Author: Dr. Emine Ünal, Department of Dermatology, Yenimahalle State Hospital, Ankara, Turkey

Published:

J Turk Acad Dermatol 2015; 9 (1): 1591c5

This article is available from: <http://www.jtad.org/2015/1/jtad1591c5.pdf>

Keywords: Blaschko's lines, lichen

Abstract

Observation: Lichen Striatus (LS) is an uncommon dermatosis characterised by a linear inflammatory papular eruption. It's frequently seen in children. It was reported in adults rarely. It usually consists of asymptomatic pink-purple papules located on either of the extremities. Pruritus may be seen rarely. Disease which can involve nails, have the feature of spontaneous regression. Although its etiology is not to be completely known; it is thought that it is an immunological response triggered by infections, environmental factors, trauma, pregnancy, vaccine and medications. We presented 65-year-old male and 55-year old female patients. Both patients applied to our polyclinic with eruption which onset suddenly and progress rapidly that is going on for 2-3 months. Lesions located on legs in male patient and on the leg and umbilicus in female patient. Lesions were located on Blaschko's lines but there were cuts in streaks. Nail examinations were normal. Male patient complained of pruritus. There was no vaccine, infection and trauma history in the patients. They had drug usage history due to hypertension and ischemic heart disease. There was no similar disease history in their family. It was the first applications of the patients. Punch biopsy was conducted. They were diagnosed as lichen striatus based on clinical and histopathological findings. Topical corticosteroid cream therapy was started to patients and they were monitored. These cases were presented on the purpose of emphasizing LS should be kept in mind in adults in differential diagnosis of linear lesions.

Introduction

Lichen striatus is an uncommon inflammatory disease that has characteristic of spontaneous regression within a year generally. It frequently presents with linear papules that are located on the extremities. Generally, it regress spontaneously within years. This dermatosis frequently affects children and is rarely seen in adults [1, 2].

Case Reports

Case 1: 65-year-old male patient applied with complaints of rash in the left leg that started two months ago. There was no family history. His physical examination was normal. In his dermatological examination, pink-purple lichenoid papules

that spreading from his left ankle to his thigh, was present (Figure 1).

Case 2: 54-year-old female patient applied with complaints of sudden onset rash in her right leg and on her umbilicus two months ago. She had drug usage history with diagnosis of hypertension. There was no one with similar complaint in her family. Her physical examination was normal. In her dermatological examination, linear-distributed lesion that formed of pink-purple papules was monitored (Figure 2). The eruption had been started on her right ankle and extended to her thigh. The lesions on her umbilicus were arranged as a linear pattern also (Figure 3).

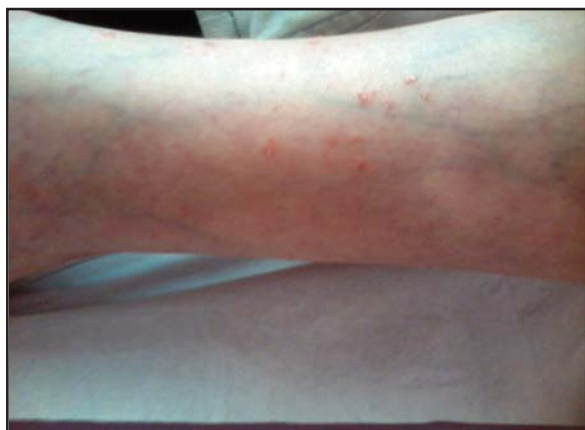

Figure 1. Pink-purple lichenoid papules on the leg

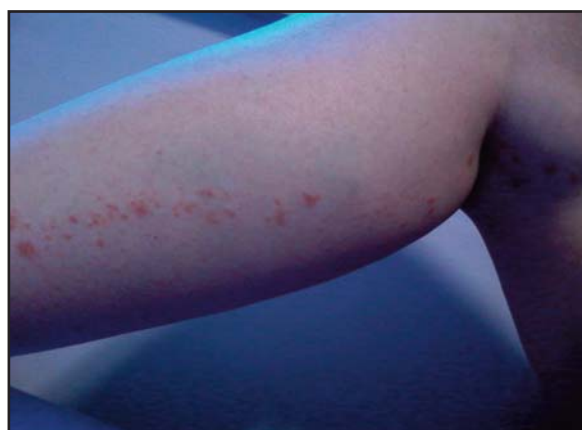

Figure 2. Linear-distributed lesion that formed of pink-purple papules

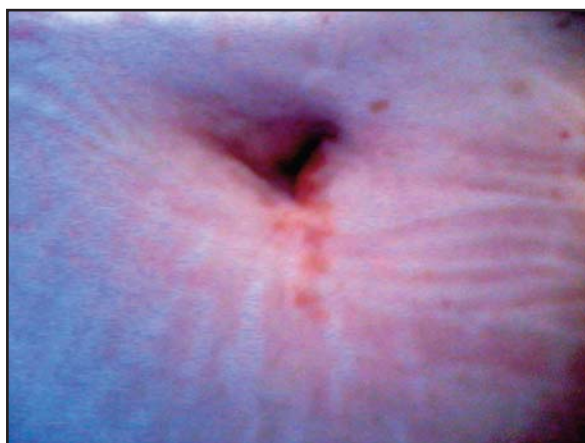

Figure 3. Pink-purple lichenoid papules arranged as a linear pattern

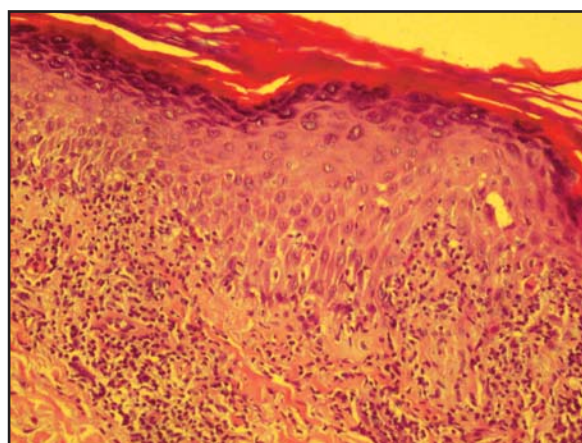


Figure 4. Hyperkeratosis, hypergranulosis, wedge shaped acanthosis and spongiosis

Discussion

Lichen striatus is an inflammatory disease that follows Blaschko's lines. It forms from 2-4 mm-sized pink-purple papules. It can also present with hypopigmented macules. Generally, there is no complaint of pruritus. Unilateral extremity involvement is frequent. Involvement of face and another region of the body were also reported. In some reports bilaterally or widespread lesions were also reported. It is frequently seen in pre-school children. In the study presented by *Hauber* and et al. [1] there were 12 patients and 9 of them were male. But when looked at the other series it was reported that LS is more frequent in women. Postinflammatory hypo-hyperpigmentation can stay. Recurrence rarely occurs and generally reported in adult cases [1,2,3,4]. Nail involvement was reported in limited

cases as onychodystrophy and longitudinal ridging. [1, 5, 6]. Its etiology is not known. Involvement of Blaschko's lines indicates post-zygotic somatic mosaicism. But, affected gen has not been known yet. Infections, environmental factors, trauma, pregnancy, atopy, vaccine and medications are accused in pathogenesis [7,8,9].

In the available literature case series about adult LS contains at least 3 patients [4]. In these case reports LS was reported more frequent in adult women. Occurrence of LS in adults had been reported after hepatitis B vaccine [7], after allogenic peripheric stem cell transplantation [9] and after solarium [10]. In these cases involvement sides were face-neck, upper extremity, trunk and lower extremity and frequency of trunk involvement was also noticeably [4, 7, 9, 10].

In differential diagnosis, dermatoses that should be most frequently considered are linear psoriasis, linear Darier's disease, linear lichen planus and inflammatory linear verrucous epidermal nevus (ILVEN). Skin biopsy is performed for distinguish this disease from other linear dermatoses [1]. A 4 mm punch biopsy was taken from patients. In histopathological examination hyperkeratosis, hypergranulosis, wedge shaped acanthosis and spongiosis were monitored. Dyskeratotic cells were present in all layers of epidermis. Band shaped infiltration of mononuclear inflammatory cells in the upper dermis was seen and this inflammation produced degeneration in epidermal basal layer (Figure 4). In the differential diagnoses according to its histopathological findings it can be easily differed from linear psoriasis. ILVEN is always pruritic and does not regress spontaneously. Another diagnosis to take into consideration is 'Adult Blaschkitis' (AB). If LS occurs in advanced age the diagnosis of adult blaschkitis has to be considered. As AB and LS show many similarities clinical and histopathological some authors believe that LS is the equivalent of adult blaschkitis in childhood [11]. Some suggest that these two diseases are different entities [12]. Because of frequent trunk involvement in adult blaschkitis and lichenoid infiltration on histopathological examination we did not think AB in our patients. We diagnosed our patients as LS according to clinicopathologic correlation.

LS is usually an asymptomatic and self-limiting disorder. Because of these reasons there is no need to treat. If there is pruritus treatment is essential then. Successful results were informed with topical corticosteroids and topical calcineurin inhibitors in the treatment [3, 4].

We presented a female and a male, two adult patients in there. Their ages were 65 and 55. Both patients did not have nail involvement. They had drug usage history because of ischemic heart disease and hypertension. Topical corticosteroid treatment was started to patients and they were monitored. Female pati-

ent's complaint recovered 3 months later after treatment, but male patient did not respond to the treatment.

Limited cases in adults are presented in literature. We stress in this report that when an eruption in a linear pattern especially on extremities we must think LS.

References

1. Hauber K, Rose C, Brocker EB, Hamm H. Lichen striatus: clinical features and follow-up in 12 patients. *Eur J Dermatol* 2000; 10: 536-539. PMID 11056425
2. Fogagnolo L, Barreto JA, Soares CT, Marinho F, Nas-sif P. Lichen striatus on adult. *An Bras Dermatol* 2011; 86 : 142-145. PMID 21437538
3. Vukicevic J, Milobratovic D, Vesic S, Jovcic-Milosevic N, Ciric D, Medenica L. Unilateral multiple lichen striatus treated with tacrolimus ointment: a case report. *Acta Dermatovenerol Alp Panonica Adriat* 2009; 18: 35-38. PMID 19350187
4. Campanati A, Brandozzi G, Giangiacomi M, Simonetti O, Marconi B, Offidani M. Lichen striatus in adults and pimecrolimus: open, off-label clinical study. *Int J Dermatol* 2008; 47: 732-736. PMID 18613885
5. Al-Niaimi FA, Cox NH. Unilateral lichen striatus with bilateral onychodystrophy. *Eur J Dermatol* 2009; 19: 511. PMID 19502159
6. Inamadara AC. Lichen striatus with nail involvement. 2001; 67: 197. *Indian J Dermatol Venereol Leprol* PMID 17664740
7. Karakas M, Durdu M, Uzun S, Karakas P, Tuncer I, Cevlik F. Lichen striatus following HBV vaccination. *J Dermatol* 2005; 32: 506-508. PMID 16043931
8. Dragos V, Mervic L, Zgavec B. Lichen striatus in a child after immunization. A case report. *Acta Dermatovenerol Alp Panonica Adriat* 2006; 15: 178-180. PMID 17982611
9. Mun JH, Park HJ, Kim HS, Ko HC, Kim BS, Kim MB. Lichen striatus occurring after allogenic peripheral blood stem cell transplantation in an adult with aplastic anemia. *Ann Dermatol* 2012; 24: 87-89. PMID 22363164
10. Cicone A, Bekhor P. Lichen striatus following solarium exposure. *Australas J Dermatol* 2007; 48 : 99-101. PMID 17535197
11. Hofer T. Lichen striatus in adults or 'adult blaschkitis'?. There is no need for a new naming. *Dermatology* 2003; 207: 89-92. PMID 12835564
12. Lee HJ, Kang WH, Hann SK. Acquired Blaschko dermatitis: acquired relapsing self-healing Blaschko dermatitis. *J Dermatol* 1996; 23: 639-642. PMID:8916667