

A Case Report of Neuroblastoma with Cutaneous Metastasis in a Two-Month-Old Infant

Mahmut Sami Metin,¹ MD, Necmettin Akdeniz,^{1*} MD, Ömer Faruk Elmas,¹ MD, Betül Gündoğdu,³ MD, Okan Kızılyel,¹ MD, Funda Taş,¹ MD, Şule Bilici,¹ MD, Haticetülkübra Efe,¹ MD, Mustafa Büyükcavcı,² MD

Address: Atatürk University, Faculty of Medicine, ¹Department of Dermatology, ²Department of Pediatrics, ³Department of Pathology, Erzurum, TURKEY

E-mail: drnakdeniz@gmail.com

* Corresponding Author: Associate Professor Necmettin Akdeniz Atatürk University, Faculty of Medicine Department of Dermatology 25240 Erzurum

Published:

J Turk Acad Dermatol 2015; **9** (1): 1591c1

This article is available from: <http://www.jtad.org/2015/1/jtad1591c1.pdf>

Keywords: Neuroblastoma, cutaneous metastasis, infant

Abstract

Observation: Neuroblastoma; is a tumour localized in adrenal medulla and sympathetic ganglions. It is originated from primitive neural crest cells. It is the most common extra cranial solid tumour in childhood. Etiology is not exactly known. Mostly, primary tumour is localized in abdomen. The skin metastases are clinically manifested as hyperemic, purple, well bordered obvious nodules. We presented a two-month-old infant case of neuroblastoma with cutaneous metastasis. We decided to report this case for cutaneous metastases are rarely seen and there are few case reports in literature.

Introduction

Neuroblastoma is a tumour that originated from primitive neural crest cells and localized on adrenal medulla and sympathetic ganglions. It is the most common extracranial solid tumour in childhood. It's about 8-10% of all childhood malignancies. Prevalence is 1 in 7000 live births [1]. Etiology is unknown exactly. The role of environmental factors is not shown [2]. Genetic studies about neuroblastoma revealed a hereditary predisposition area in short arm of 16th chromosome [3, 4, 5, 6]. Neuroblastoma is a tumour of sympathetic nerve system and can see in anywhere during sympathetic neural way. Mostly, the primary tumour is seen in abdomen (65%) and the most common complaint is asymptomatic abdominal mass. Adrenal localization is seen more frequently in children (40%) than infants (25%) [7, 8, 9, 10]. Surgery is the

main treatment option. The surgery is required for diagnosis, staging and removal of tumour. After diagnosis, chemotherapy and radiotherapy are treatment options. The cases are rare which presenting as subcuta-

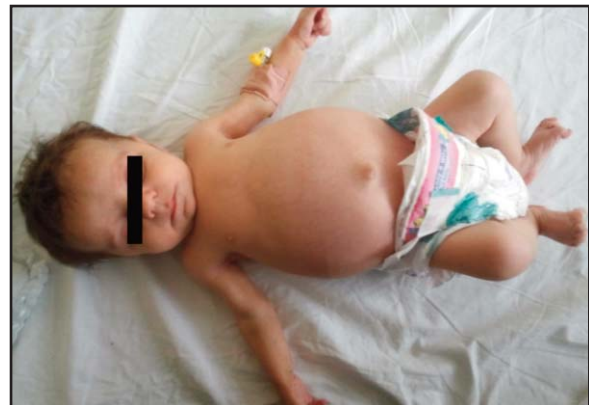

Figure 1. Abdomen was distended due to the mass which is created by adrenal neuroblastoma

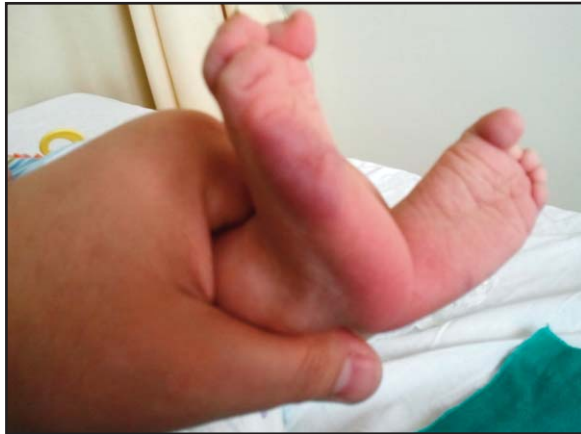

Figure 2. There is a 3x2 cm sized purple-colored nodule on the lateral aspect of plantar area of the right foot

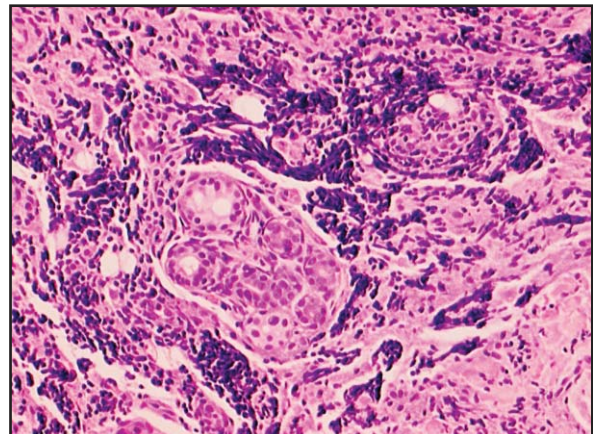


Figure 3. (H&E,x10) Atypical cells which are mitotically active and have narrow cytoplasm and round nuclei, formed small rosette formation

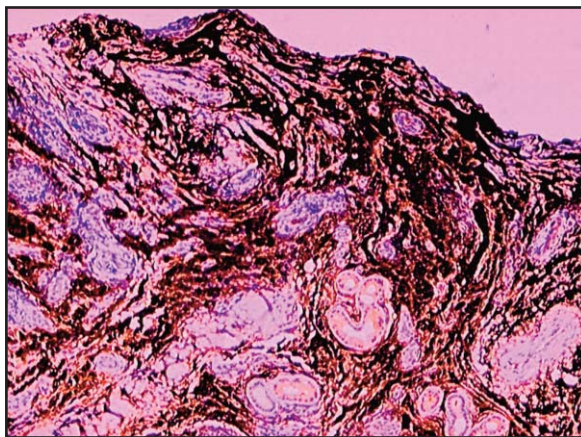


Figure 4. Chromogranin positive nuclei in the neoplastic tissue

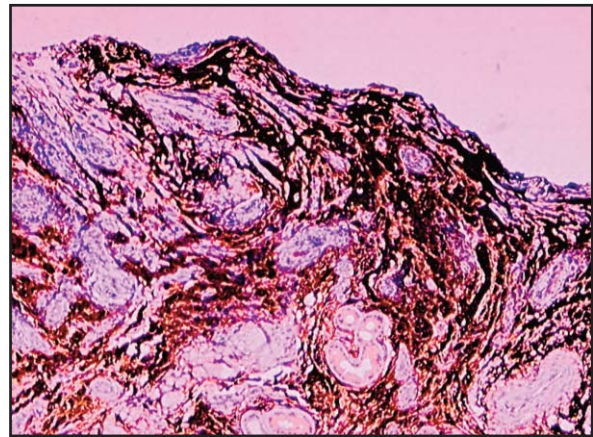


Figure 5. NSE positive neoplastic tissue

neous nodules [11]. The skin metastases of neuroblastoma are characterized as hyperemic, purplish and well-defined nodules. Palpations of nodules along 2-3 minutes cause a pale color. This sign is probably caused by vasoconstrictive effects of catecholamine that released from tumour cells and it is characteristic feature for neuroblastoma [12,13,14]. Because cutaneous metastasis is rare in neuroblastoma and there are inadequately numbers of case in literature about neuroblastoma with cutaneous metastasis, we decided to report this case.

Case Report

Two month old infant had admitted to pediatric hematology clinic. The patient was hospitalized with vomiting including food, excessive crying and absence of suckling. These complaints have begun from birth. The prenatal history of patients was normal except positivity of triple screening test.

There wasn't any family history. Systemic physical examination revealed abdominal distention and hepatomegaly (Figure 1). Laboratory investigation revealed these results: Hemoglobin: 7, LDH: 632, in spot urine analyze; metanephrine :489 , normetanephrine: 521, norepinephrine: 389, Dopamine: 421, Epinephrine: 63, HVA: 31, VMA: 41, 5-HIAA: 53. 7. On abdominal CT scanning, liver was larger than normal, with 135 mm and there were multiple ill-defined metastatic focuses in almost all parenchyma segments. The largest of metastatic lesion was 4 cm in diameter and localized at seventh segment. There was heterogen, well defined; 3.5 cm in diameter mass lesion image on surrenal CT scanning of thorax and brain MRI was reported normally. At the third day of hospitalization, patient was consulted to our clinic with plantar skin rashes. Dermatological examination of right foot revealed approximately 3x2 cm in diameter firm, erythematous, mass lesion (Figure 2). Biopsy was taken from cutaneous mass that considered initial diagnosis of metastasis. Histological examination of biopsy specimen showed a neoplastic process

that consist mitotically active, narrow cytoplasmic, small and round nucleated atypical cells (**Figure 3**). Atypical cells stained chromogranin positive (**Figure 4**), NSE weakly positive (**Figure 5**) and S-100 negative. Histological investigation was reported as cutaneous metastasis of neuroblastoma.

Discussion

Neuroblastoma is the most common extracranial solid tumor of infancy. It is an embryonal malignancy of the sympathetic nervous system arising from neuroblasts (pluripotent sympathetic cells) [1]. On the instant of diagnosis, 75% of patients have metastasis [7]. Metastasis occurs with lymphatic and hematogenous ways. In 35% patients who have localized tumour, regional lymph node metastasis can be seen. Occurrence of this condition without metastasis to other region shows good prognosis [8]. Cutaneous metastases are rarely seen and there are few case reports in literature. *Wesche et al.* reported that 8 of the 34 pediatric oncology patients were neuroblastoma [15]. *Demirkaya et al.* reported that 3 day old boy baby patient had a neuroblastoma. In this case neuroblastoma had spread to liver and skin [1]. The skin metastases were localized in the back and he had 5 ads, 4x5 cm in diameter subcutaneous nodules. The urine catecholamine and catecholamine breakdown products had evaluated normally. But in our case, levels of urine catecholamine and catecholamine breakdown products had increased. In our case, the patient similarly had liver and skin metastasis. In case of *Gunes et al.* reported 6 day old boy who presented as jaundice [13]. His abdominal mass had evaluated as neuroblastoma. He had common skin metastasis on his trunk. In a case of *Chen et al.* reported, 47 day old boy had presented as a numerous subcutaneous nodules from 2 week after birth [14]. In this case patient had liver and skin metastases. In laboratory investigation, VMA and LDH levels had increased. In our case, these parameters similarly had increased and he had liver and skin metastasis. When the importance of early diagnosis and its effects on prognosis was taken into account, the subcutaneous nodules in infants should be considered for probability of neuroblastoma metastasis. Neuroblastoma can obtain early through careful physical examination and biopsy. In recent years, the screen tests for catecholamine and its break-

down products in order to early diagnosis of neuroblastoma has been discussed.

Conclusion

An awareness of the cutaneous metastases of neuroblastoma should result in the diagnosis of an underlying cancer in infant.

References

- Demirkaya M, Sevinir B. Nöroblastom. *Güncel Pediatri* 2006; 3: 128-132.
- Knudson AG Jr, Strong LC. Mutation and cancer: neuroblastoma and pheochromocytoma. *Am J Hum Genet* 1972; 24: 514-532. PMID: 4340974
- Maris JM, Weiss MJ, Mosse Y, et al. Evidence for a hereditary neuroblastoma predisposition locus at chromosome 16p12-13. *Cancer Res* 2002; 62: 6651-6658. PMID: 12438263
- Gehring M, Berthold F, Edler L, Schwab M, Amler LC. The 1p deletion is not a reliable marker for the prognosis of patients with neuroblastoma. *Cancer Res* 1995; 55: 5366-5369. PMID: 7585602
- Martinsson T, Sjöberg RM, Hedborg F, Kogner P. Deletion of chromosome 1p loci and microsatellite instability in neuroblastomas analyzed with short-tandem repeat polymorphisms. *Cancer Res* 1995; 55: 5681-5686. PMID: 7585654
- White PS, Thompson PM, Gotoh T, et al. Definition and characterization of a region of 1p36.3 consistently deleted in neuroblastoma. *Oncogene* 2005; 24: 2684-2694. PMID: 15829979
- Brodeur GM, Maris JM. Neuroblastoma. In: *Principles and Practice of Pediatric Oncology*. Pizzo PA, Poplack DG (eds). 4th edition. Philadelphia PA: Lippincott Williams & Wilkins, 2001: 933-970.
- Yamada S, Ishii E, Nakagawara A, et al. Features and outcome of advanced neuroblastoma with distant lymph node metastasis. *Pediatr Hematol Oncol* 1992; 9: 49-56. PMID: 1558776
- Kaplan SJ, Holbrook CT, McDaniel HG, Buntain WL, Crist WM. Vasoactive intestinal peptide secreting tumors of childhood. *Am J Dis Child* 1980; 134: 21-24. PMID: 6101297
- Rudnick E, Khakoo Y, Antunes NL, et al. Opsoclonus-myoclonus-ataxia syndrome in neuroblastoma: clinical outcome and antineuronal antibodies-a report from the Children's Cancer Group Study. *Med Pediatr Oncol* 2001; 36: 612-622. PMID: 11344492
- Fender AB, Gust A, Wang N, Scott GA, Mercurio MG. Congenital leukemia cutis. *Pediatr Dermatol* 2008; 25: 34-37. PMID: 18304150
- Maher-Wiese VL, Wenner NP, Grant-Kels JM. Metastatic Cutaneous lesions in children and adolescents with a case report of metastatic neuroblastoma. *J Am Acad Dermatol* 1992; 26: 620-628. PMID: 1597549
- Güneş T, Akçakuş M, Çetin N, Patıroğlu T, Kotaş O. Cilt metastazları ile seyreden bir konjenital nöroblas-

- tom vakası. Turkiye Klinikleri J Peditr Sci 2002; 11: 96-99.
14. Chen CJ, Hwang S.H, Hung IC, Wang YH, Chen WD, Liao KK. Metastatic neuroblastoma presenting as cutaneous nodules. Dermatol Sinica 1993; 11: 105-111
15. Wesche WA, Khare VK, Chesney TM, JenkinsJJ. Non-hematopoietic cutaneous metastases in children and adolescents: thirty years experience at St. Jude Children's Research Hospital. J Cutan Pathol 2000; 27: 485-492. PMID: 11100807