

Sebaceous Hyperplasia en plaque: A Rare Variant

Aslı Hapa,¹ MD, Duygu Gülseren,² MD, Gül Erkin,³ MD, Özay Gököz,⁴ MD

Address: ¹Sifa University, Faculty of Medicine, Department of Dermatology, Gazimir, İzmir, ²Polatlı Duatepe State Hospital, Polatlı, ³Private Güven Hospital, Dermatology Clinic, ⁴Hacettepe University, Faculty of Medicine, Department of Pathology, Ankara, Turkey.

E-mail: draltaykan@yahoo.com

* Corresponding Author: Dr. Aslı Hapa, Sifa University, Faculty of Medicine, Department of Dermatology, Gazimir, İzmir, Turkey.

Published:

J Turk Acad Dermatol 2016; 10 (3): 16103c4

This article is available from: <http://www.jtad.org/2016/3/jtad16103c4.pdf>

Keywords: Sebaceous hyperplasia, plaque

Abstract

Observation: We present a rare variant of sebaceous hyperplasia in the postauricular area presenting with yellowish papules coalescing to form a plaque. We would like to present this unique case because of its plaque like formation of the sebaceous papules as well as its rare localization in the retroauricular region.

Introduction

Sebaceous hyperplasia (SH) occurs frequently as solitary or multiple yellowish papules on the face in adults of middle age and older [1]. We present here a rare variant of sebaceous hyperplasia in the postauricular area presenting with yellowish papules coalescing to form a plaque.

Case Report

A 20-year-old female presented with asymptomatic skin lesions in the postauricular area for 2 years. She was otherwise healthy. Dermatological examination revealed multiple yellowish papules coalescing to form plaque on the left postauricular region (Figure 1). A 4-mm-punch biopsy was made from one of the yellowish papules which revealed hyperplastic sebaceous glands (Figure 2). The diagnosis was sebaceous hyperplasia en plaque.

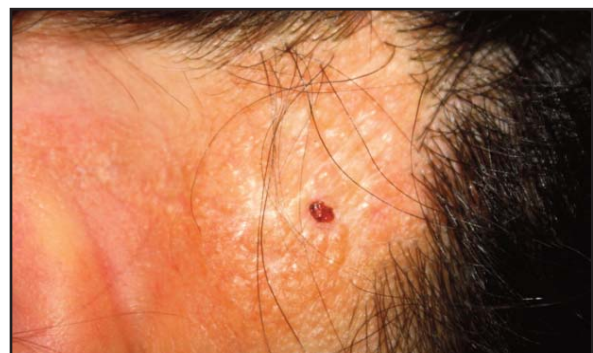

Figure 1. Multiple yellowish papules coalescing to form plaques on the left postauricular region (4 mm-punch biopsy site is seen on the middle of the plaque)

Discussion

Sebaceous hyperplasia occurs frequently as solitary or multiple yellowish papules on the face in adults of middle age and older [1]. Recently, several cases in adolescence and

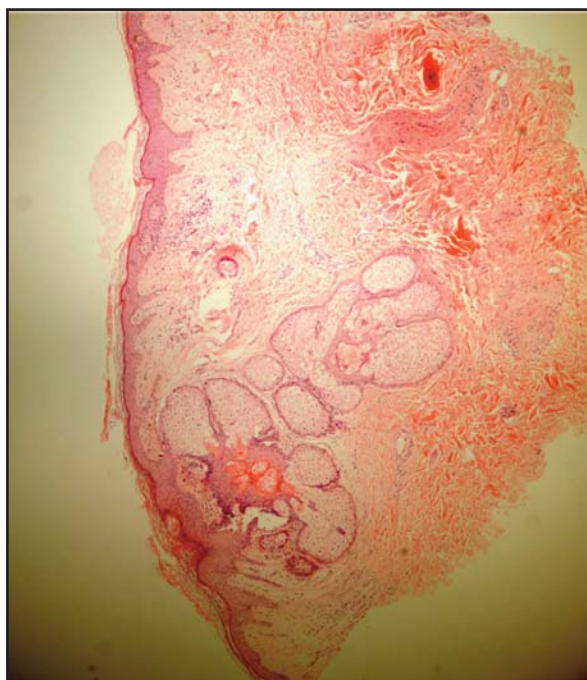


Figure 2. A conspicuous sebaceous gland with holocrine degeneration on the background of normal skin (HEX100)

young adult patients have been described and identified as premature sebaceous gland hyperplasia [2]. The pathogenesis of this early clinical variant seems to be different from the senile type and it is poorly understood. Some reports have documented a family history [3]. In addition to this early clinical variant of sebaceous hyperplasia, several more clinical variants have been reported. There are patients with a giant form [4] on the cheek and also with linear arrangement [5]. Similar to our case, patients who had grouped hyperplastic sebaceous glands in a plaque pattern were rarely described [6].

The most frequent localizations of the senile and premature type of SH are the face, neck and upper thorax [2]. However, reports of SH

on atypical localizations such as areola [7], vulva [8] and penis [9] have been described. To the best of our knowledge, the only report with SH forming a plaque around auricular region apart from our case is the one described by Kim et al [6].

However, SH is thought to be associated with decreased androgen levels in aging individuals and the pathogenesis of these early and unusual variants remain unknown. In conclusion, we would like to present this unique case because of its plaque like formation of the sebaceous papules as well as its rare localization in the retroauricular region.

References

1. McCalmont TM. Adnexal neoplasms. In: Dermatology. Bologna JL, Jorizzo JL, Schaffer JV, editors. 3rd ed. China: Elsevier, 2012, 1839-1840.
2. Turan H1, Erdem H, Turan A, Kadioglu N, Basar F. Premature sebaceous hyperplasia with pre-pubertal onset. *Int J Dermatol* 2014; 53: e224-226. PMID: 23829474
3. Boochai W, Leenutophong V. Familial presenile sebaceous gland hyperplasia. *J Am Acad Dermatol* 1997; 36: 120-122. PMID: 8996280
4. Kato N, Yasuoka A. Giant senile sebaceous hyperplasia. *J Dermatol* 1992, 19: 238-241. PMID: 1607487
5. Jeong TJ, Shin MK, Lee MH. Linear sebaceous hyperplasia on the chest. *Clin Exp Dermatol* 2009, 34: e366-367. PMID: 19489857
6. Kim HS, Lee HJ, Lee JY, Kim HO, Park YM. Papular skin lesions in the retroauricular area: A quiz. Premature sebaceous hyperplasia en plaque. *Acta Derm Venereol* 2010; 90: 223-224. PMID: 20169325
7. Carmen FM, Luisa SM, Pilar E, Enric P, Lucia M. Unilateral areolar sebaceous hyperplasia in a male. *Am J Dermatopathol* 1996; 18: 417-419.
8. Malliah R, Gilhooly P, Lambert WC, Heller DS. Sebaceous hyperplasia of the vulva: Case report and review of the literature. *J Low Gen Tract Disease* 2006; 10: 55-57. PMID: 16378033
9. Kumar A, Kossard S. Band-like sebaceous hyperplasia over the penis. *Aust J Dermatol* 1999; 40: 47-48. PMID: 10098291