

Primary Systemic Amyloidosis Associated with Smoldering Myeloma: A Case Report

Kıymet Handan Kelekçi,^{1*} MD, Güngör Yılmaz,¹ MD, Ali Karakuzu,¹ MD, Şemsettin Karaca,¹ MD, Murat Ermete,² MD, Füsün Özdemirkıran,³ MD

Address: ¹İzmir Katip Çelebi University, Atatürk Education and Research Hospital, Department of Dermatology,

²Department of Pathology, ³Department of Hematology, İzmir, Turkey

E-mail: drhandankelekci@yahoo.com

* Corresponding Author: Dr. Kıymet Handan Kelekci, İzmir Katip Çelebi University, Atatürk Education and Research Hospital, Department of Dermatology, İzmir, Turkey

Published:

J Turk Acad Dermatol 2016; 10 (4): 16104c2

This article is available from: <http://www.jtad.org/2016/4/jtad16104c2.pdf>

Keywords: Amyloidosis, smoldering myeloma

Abstract

Observation: Amyloidosis is a clinical disorder caused by extracellular and/or intracellular deposition of insoluble abnormal amyloid fibrils derived from the aggregation of misfolded plasma protein. Primary systemic amyloidosis (PSA) are typically developed from AL proteins that are λ light chains of immunoglobulins. Amyloid fibrils in PSA are progressively collected in tissues and they disrupt the structure and function of organs. The most commonly affected organs are heart, kidneys, gastrointestinal system, liver, lung, peripheral and autonomic nervous system. Smoldering multiple myeloma (asymptomatic multiple myeloma) refers an increment of serum monoclonal protein level and plasma cells in the bone marrow, or both in the absence of as hypercalcemia, renal insufficiency, anemia, lytic bone lesions related to plasma-cell disorders. We presented herein, a case of PSA associated with smoldering myeloma because it's rare disease and it's interesting due to diagnosis is delayed before cutaneous finding are appeared.

Introduction

Amyloidosis is a disease that characterized by extracellular deposition of polymerizable soluble protein fibrils in tissues and organs. Systemic amyloidosis can be grouped as primary, secondary and familial [1, 2]. Petechiae, purpura, ecchymosis, yellowish papules and nodules can be seen in Primary systemic amyloidosis (PSA) due to the involvement of blood vessels in the skin. Common sites of dermal amyloid deposition are especially in the skin of eyelid, behind the ears, neck, axilla, the inframammary skin, umbilicus, inguinal and anogenital region, lips, tongue and buccal mucosa. Although primary systemic

amyloidosis does not consist all criteria of multiple myeloma, it may occur as a symptom of plasma cell disorder [2].

Case Report

A 79-year-old woman was attended to the dermatology outpatient clinic because of growth of tongue and blisters on the inside of lips. In the history patient stated about weakness and growth of tongue for about a few months. She had hypertension, pain of her joint and an operation from both wrists for carpal tunnel syndrome. She had suffered acute myocardial infarction two years ago. During the dermatologic examination, plaques on the both eyelids that are formed from ecchymosis

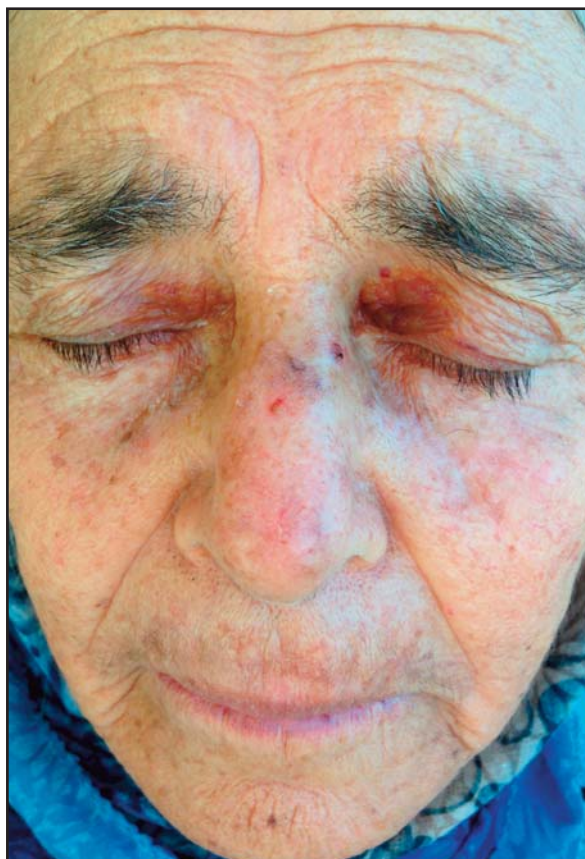

Figure 1. Translucent and waxy yellowish papules with underlying ecchymoses on periorbital region

areas accompanying asymptomatic yellowish papules and inside the lower lip are observed (**Figures 1 and 2**). Gray-brown papular lesions were seen on the gluteal region and around the anus (**Figure 3**). Hematoxylin and eosin staining was demonstrated intense eosinophilic amyloid deposition that is characterized with long and thin cleavages; from the dermal biopsy obtained from tongue, internal part of lower lip and gluteal area. In the immunohistochemistry positively staining with Congo red, AL amyloid accumulation with orange and light brown colors and typical image of amyloid with apple-green color staining, under polarized light has been showed (**Figures 4a, b and c**). Amyloid deposits in abdominal subcutaneous fat biopsy performed negative. Complete blood count tests (platelet: $376 \times 10^9/l$, leucocyte: $10 \times 10^9/l$, sedimentation: 38 mm/hour) increased borderline. Biochemical tests included serum albumin, globulin, lactic dehydrogenase, calcium, renal and liver function tests, and posterior anterior lung graphy were evaluated as normal. Mild proteinuria identified on 24 hours urine test with result of 20 mg/dl (Normal: $1-14$). In serum and 24-hour urine immunofixation electrophoresis confirmed immunoglobulin kappa light chain mo-

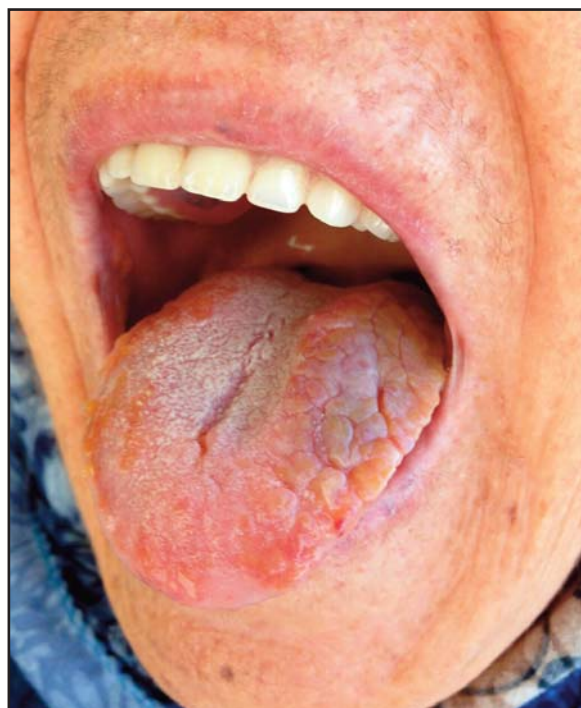

Figure 2. Primary systemic amyloidosis with involvement tongue

noclonal gammopathy. Increasing in serum kappa light chain (102 mg/dl normal: $6,7-22,4$) and lambda chain ($36,6 \text{ mg/dl}$ normal: $8,3-27$), reduction of Ig M ($22,6 \text{ mg/dl}$ normal: $56-352$), IgA ($51,8 \text{ mg/dl}$ normal: $70-312$) was found. In the form of CD38 and CD138 positive focal cluster, 15% plasma cell infiltration was observed in bone marrow biopsy. Amyloid deposition was not showed in the bone marrow and endoscopic biopsy of the rectum. Any osteolytic lesion was not detected in bone survey. In echocardiographic examination; ejection fraction was 60%; minimal mitral insufficiency, first degree aortic insufficiency were showed but any hyperechogenicity was not found suggesting amyloid deposition. Electromyography (EMG) for evaluation of polyneuropathy was normal. Finally, our patient was diagnosed as PSA associated with smoldering multiple myeloma clinically, histopathologically and blood analysis. We recommended to the patient about advanced cardiac evaluation (cardiac magnetic resonance imaging) but patient did not accept. Moreover the patient has not come to follow up after than last visit.

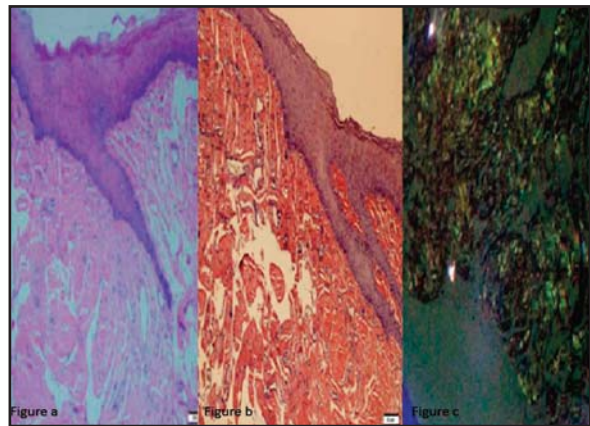
Discussion

Primary systemic amyloidosis or light chain amyloidosis (AL) is a disease characterized by the clonal population bone marrow monoclonal plasma cells producing types of kappa

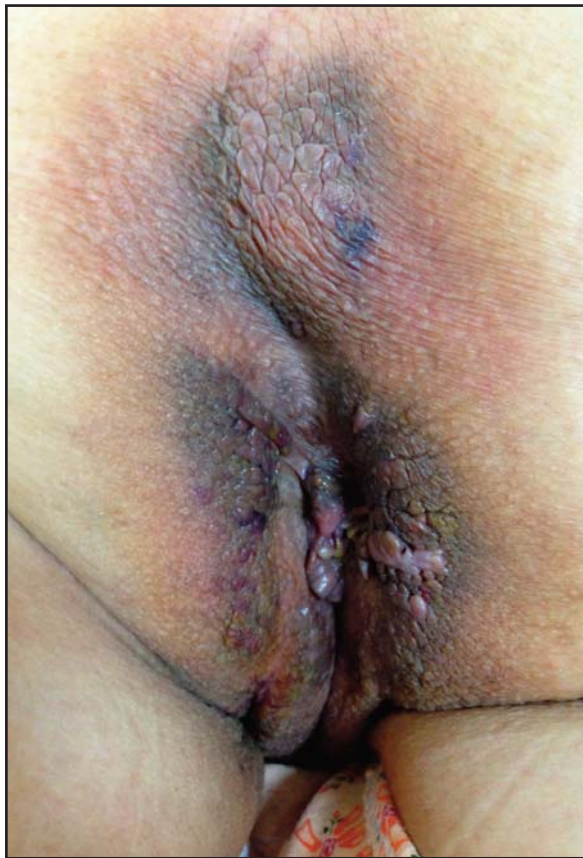

Figure 3. Gray-brown papules on the gluteal region and around the anus

and lambda light chain [3]. The exact etiopathogenesis of amyloid formation remains unclear [4]. It's also called Lubarsh-Pick disease, occurs usually after age 50 and has a 3:1 male-female ratio. The prevalence of amyloidosis associated with multiple myeloma varies between 13-26%. In 15% of patients with multiple myeloma develop amyloidosis [1, 5]. Although AL amyloidosis diagnosed patients with multiple myeloma, 80% of them does not fulfill the criteria [6]. Smoldering multiple myeloma is an asymptomatic proliferative disorders plasma cells with a high risk of progression to multiple myeloma. It refers an increment of serum monoclonal protein level of 3 g per deciliter or more, 10% or more plasma cells in the bone marrow, or both in the absence of as hypercalcemia, renal insufficiency, anemia, lytic bone lesions related to plasma-cell disorders [7]. Kyle et al. reported in one study of 494 cases of PSA only 3% of cases were associated with smoldering multiple myeloma [6]. In the patient serum protein electrophoresis and immunofixation



Figures 4a, b and c. (a) Intense eosinophilic amyloid deposition with long and thin cleavages.(H&E×200), (b) Congo red dye revealing orange and light brown staining of amyloid substance.(H&E×200), (c) Congo red stain showed typical image of amyloid with apple-green birefringence under polarized light microscope

tests immunoglobulin kappa light chain monoclonal gammopathy was found. Identification of 15% atypical plasma cells in bone marrow biopsy, were consistent with smoldering multiple myeloma.

Skin findings are atypical in PSA and the first major symptoms usually do not appear as [1]. The most common skin manifestations are petechiae, purpura, ecchymosis, waxy yellow translucent papules, plaques, nodules [2]. Amyloid accumulation in the periorbital region and tongue is an important manifestation of the disease by trauma or spontaneously developed. Waxy papules, plaques and nodules on tongue can cause macroglossia [5, 7]. Macroglossia is seen in approximately 10% of patients with AL amyloidosis and it is pathognomonic for disease [2]. Other rare cutaneous conditions are hyperpigmentation, infiltrate similar to scleroderma, alopecia, nail dystrophies, cutis laxa and lesions similar to cutis verticis girata [2, 5]. Our patient had ecchymosis lesions on the periorbital and she had also yellow translucent waxy papules and plaques which tend to coalesce on the eyelids, tongue and the inside of lower lip.

Clinical systemic manifestations of amyloidosis variable, it can be complicated or unclear but nonspecific malaise, and weight loss is found in almost all of patients [1, 8].

Accumulation of insoluble AL in heart, kidneys, blood vessels, liver, spleen, bone marrow and peripheral autonomic nervous system can result fatigue, tiredness and weight loss progressing a multi organ failure. Carpal tunnel syndrome is seen in 25% of PSA cases and often occurs bilaterally. It can affect peripheral nervous system [9]. Our patient also underwent an operation had both wrist with carpal tunnel syndrome. Subcutaneous abdominal fat aspiration is the preferred method for detection of amyloidosis with sensitivity of 80% [2]. Our patient was negative for amyloid deposition in the abdominal fat aspiration.

Patients are often misdiagnosed because of clinical lesions of systemic amyloidosis may vary depending on the location of accumulated amyloid proteins. Histopathology of skin lesions are diagnosed easily with amyloid deposition in the skin and cornerstone for early diagnosis for amyloidosis [1]. In histology metachromasia is detected with crystal violet staining also the presence of eosinophilia observed in Congo red and thioflavin staining. Positivity of PAS is observed. Apple-green coloris seen in polarized light with Congo red staining [4]. Amyloidosis, porphyria, colloid millium, and lipid proteinosis included in a differential of metabolic processes involved in endogenous deposition that occur as isolated entities or part of systemic diseases [7]. It can be easy to identify amyloidosis with accumulation of AL protein in PSA.

Still there is no valid specific treatment for PSA but supportive treatments are performed today. It is aimed at maintaining the quality of life and prolonging survival [10]. Patients with amyloid related organ dysfunction often require multidisciplinary team. Although hematologic responses have become more frequent, but organ improved evolves over months to years [3]. For AL amyloidosis, autologous bone marrow transplantation therapy and high-dose melphalan with dexamethasone responded well. In addition, bortezomib, lenalidomide and talidomide-based treatments have been tried [3, 9]. In generally, smoldering multiple myeloma is followed up of a few months in terms of activated multiple myeloma [6]. However, PSA has poor prognosis, with a median survival of

13 to 43 months later death can result [8]. Unfortunately, our patient didn't accept any therapy owing to the fact that her lesions didn't cause any significant complaint.

Primary systemic amyloidosis is uncommon disease which manifestation of disease usually is slowly progressive course hence, it usually overlooked and delayed diagnose. We are presenting this uncommon case because of its apparent cutaneous and mucosal findings are very important for absolutely correct diagnosing of underlying PSA accompanied with smoldering multiple myeloma.

Conflict of Interest

All authors declare the absence of financial support of conflict of interest.

References

1. Zhao JY, Zhang RN, Duan XH, Xu ZL, Li HW, Gu FS. A case of systemic amyloidosis beginning with purpura. *Chin Med J (Engl)* 2012; 125: 555-557. PMID: 22490423
2. Kumar S, Sengupta RS, Kakkar N, Sharma A, Singh S, Varma S. Skin involvement in primary systemic amyloidosis. *Mediterr J Hematol Infect Dis* 2013; 5: e2013005.
3. Rosenzweig M, Landau H. Light chain (AL) amyloidosis: update on diagnosis and management. *J Hematol Oncol* 2011, 4: 47-48. PMID: 22100031
4. Schremml S, Szeimies R-m, Vogt T, Landthaler M, Schroeder J, Babilas P. Cutaneous amyloidoses and systemic amyloidoses with cutaneous involvement. *Eur J Dermatol* 2010; 20:152-160. PMID: 20071301
5. Oliveira EV, Pozetti AC, Pozetti EM, Antonio JR, Michalany NS. Primary systemic amyloidosis associated with multiple myeloma. *An Bras Dermatol* 2012; 87: 119-122. PMID: 22481660
6. Kyle RA, Gertz MA. Primary systemic amyloidosis: clinical and laboratory features in 474 cases. *Semin Hematol* 1995; 32: 45-14. PMID: 7878478
7. Kyle RA, Remstein ED, Therneau TM, et al. Clinical course and prognosis of smoldering (Asymptomatic) multiple myeloma. *N Engl J Med* 2007; 356: 2582-2590. PMID: 17582068
8. Mason AR, Rackoff EM, Pollack RB. Primary systemic amyloidosis associated with multiple myeloma: A Case Report and Review of the Literature. *Cutis* 2007; 80: 193-200. PMID: 17956007
9. Alvarez-Ruiz SB, García-Río I, Daudén E. [Systemic amyloidoses]. *Actas Dermosifiliogr* 2005; 96: 69-82. PMID: 16476341
10. Palladinia G, Perfettib V, Merlinia G. Therapy and management of systemic AL (primary) amyloidosis. *Swiss Med Wkly* 2006; 136: 715-720. PMID: 17183435